



# International Journal of Medical Research & Health Sciences

www.ijmrhs.com Volume 2 Issue 2 April-June Coden: IJMRHS Copyright @2013 ISSN: 2319-5886

Received: 8<sup>th</sup> Jan 2013

Revised: 28<sup>th</sup> Jan 2013

Accepted: 9<sup>th</sup> Feb 2013

## Case report

### A RARE CASE OF NEUROLIPOMA

\*Bharati P Baviskar<sup>1</sup>, Suryakant D Dongre<sup>2</sup>, Vishnu SYadkikar<sup>3</sup>

<sup>1</sup>Associate Professor, <sup>2</sup>Professor & Head, Department of Pathology, Pravara Institute of Medical Sciences, Loni. <sup>3</sup> Professor, Department of Orthopaedics, Pravara Institute of Medical Sciences, Loni.

\* Corresponding author email: baviskar.bharati@gmail.com

## ABSTRACT

A painful swelling over the left ankle joint was excised. Histopathology revealed it to be a neurolipoma. This case is reported here for its uncommon site that is involvement peroneal nerve, no association with skeletal deformity and occurrence in a male patient.

**Key Words:** Neurolipoma, Neurafibrolipoma, Lipomatosis of nerve, Fibrolipomatous Hamartoma.

## INTRODUCTION

Neurolipoma usually manifests as a soft, slowly growing mass consisting of proliferating fibrous fatty tissue surrounding and infiltrating major nerves and their branches. Principally it involves volar aspect of the hands and wrist. Lower extremity cases are extremely rare.<sup>1</sup> Median nerve is most commonly involved. The unusual sites of involvement are radial, peroneal and cranial nerves. Males are more affected than females. The lesion is almost seen during first three decades of life. About one third of cases are associated with overgrowth of bone and macrodactyly.

We report here a rare case involving peroneal nerve without any skeletal deformity occurring in a young male patient.

## CASE

A 15 years male presented with a swelling over the left ankle. The swelling was 5 x 4cm, soft to firm in consistency, globular in appearance and painful. It was gradually increasing in size.

X ray of left ankle joint revealed normal bones and soft tissue swelling around ankle joint. No other abnormalities of bone were found.

Grossly a single yellow white, fibro-fatty mass of 5 x 4 x 0.4 cm soft to firm in consistency was received. Microscopy showed mature adipose tissue admixed with fibrous tissue dissecting between and separating individual nerve bundles. Perineural fibrous tissue was seen arranged concentrically around the mass. No evidence of lipoblastic activity or cellular

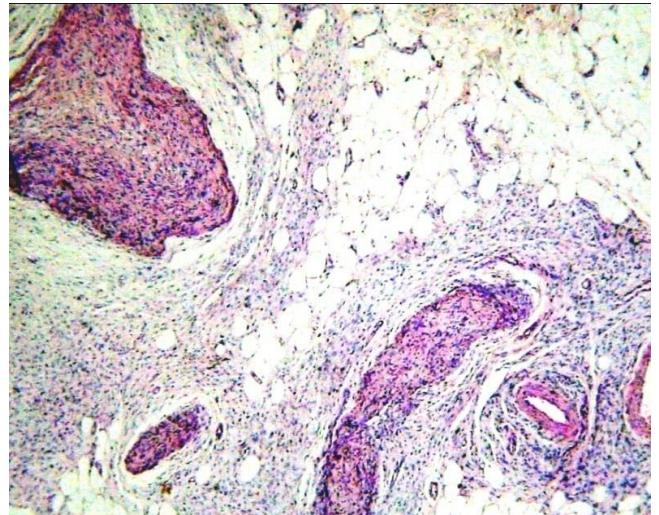
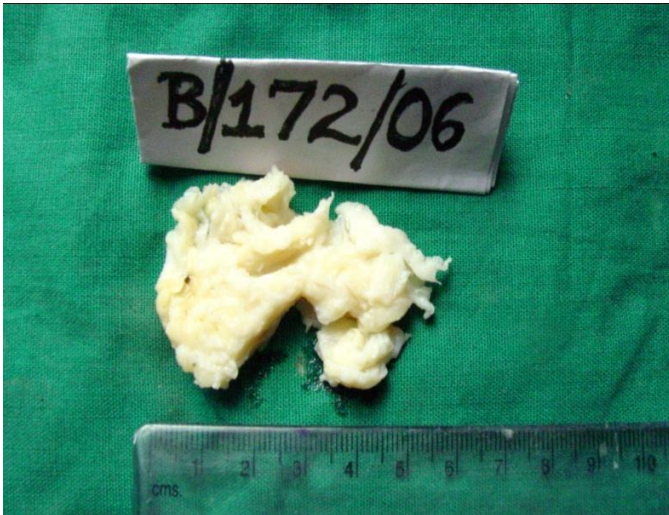
pleomorphism was seen. The diagnosis was given as Neurolipoma.

### **Etiology**

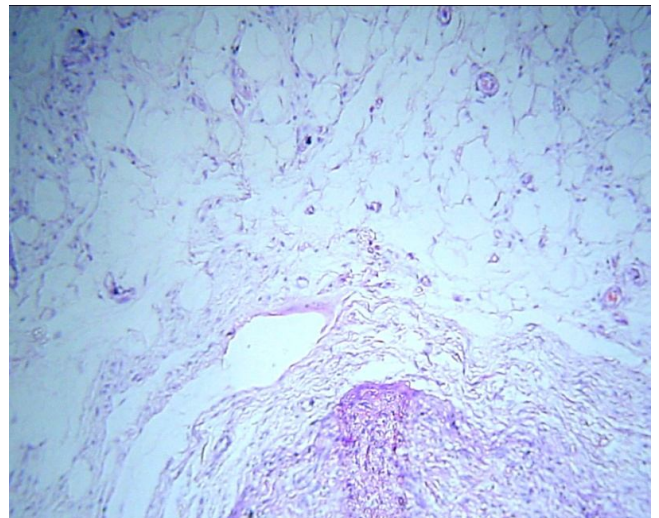
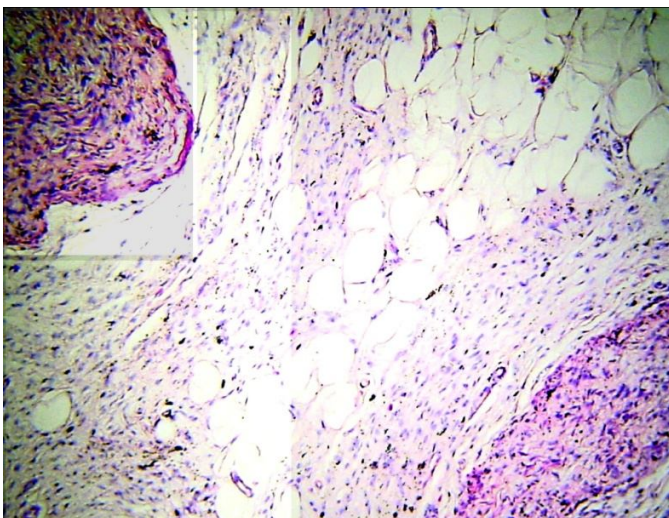
Neurolipoma is also known as neural fibrolipoma, fibrolipomatous hamartoma,

intramural lipoma, lipomatosis of nerve.<sup>2</sup>

Etiology is unknown. There may be a genetic disorder but there is no history of any hereditary disorder/syndrome. There is a history of trauma in some cases.



**Fig:1. Tumour showing yellow fatty and shiny white areas. Fig:2. Adipose tissue admixed with fibrous tissue**



**Fig:3. Proliferating nerve with adipocytes. (100X)  
DISCUSSION**

**Fig:4. Adipose tissue, neural tissue and fibroblasts (400X)**

The median nerve is affected in most cases.<sup>3,4</sup> Rarely lesions are found in other nerves such as ulnar, radial. Peroneal and cranial nerves are involved very rarely.<sup>5,6</sup> Grossly it appears as a soft, gray yellow, fusiform, sausage shaped mass that has diffusely infiltrated and replaced portion of a large nerve and its branches. Microscopically

neurolipoma shows adipose and fibrous tissue between and around nerve bundles. The diffuse infiltrative character of the lesion is pathognomonic. Fibrofatty tissue may be seen outside the involved nerve. There is marked thickening of the perineurium. A rare case may show foci of metaplastic bone. Though immunohistochemistry is not essential for diagnosis;

immunohistochemical profile of neurofibrolipoma was first reported by Akisue et al in his case report in 2002 showing CD34 antigen reactivity on fibrous spindle cells.<sup>7</sup> No ultrastructural finding is conclusive.

Lipoma of peripheral nerves occur with sufficient frequency to pose problems in diagnosis.<sup>8</sup> In lipoma of a nerve there is fat around nerve without infiltration within nerve bundles. A clear distinction from diffuse lipomatosis with overgrowth of bone is not always possible histologically, but diffuse lipomatosis is a primary lesion of the subcutis and muscle and only secondarily affects nerves.<sup>9</sup> Neuroma and neurofibroma can be distinguished from neurolipoma by nerve element. Neuroma and neurofibroma shows proliferation of neural elements while neurolipoma shows atrophy of nerve bundles.

It is usually seen in the age group of 11-39 years. Females predominate when lipofibroma is accompanied by macrodactyly, whereas males are more commonly affected when macrodactyly is absent. The present case has occurred in 15 year male. There is usually a slow growing mass present. The patient may show increasing pain, tenderness, diminished sensation or paraesthesia associated with gradually increasing mass causing compression neuropathy.<sup>10,11</sup> There may be loss of muscle strength. MRI scans are characteristic and pathognomic and it can be diagnosed preoperatively.<sup>12</sup>

Carpal tunnel syndrome is a late complication of some lesions. Pain and sensory loss may be partially or completely relieved by dividing the transverse carpal ligament and decompressing the nerve. The tumour was excised by careful dissection and separating clearly from the neurovascular bundle followed by repositioning of tendons. The initial complaint of pain was relieved and mobility was restored.

## ACKNOWLEDGEMENT

We acknowledge the support and academic guidance of Dr. Baviskar PK, Dr. Baviskar MP, Dr. Karle RR, Dr. Pandure MM.

## REFERENCES

1. Neural fibrolipoma In: Benign Lipomatous tumors. Enzinger and Weiss Soft tissue tumors, 4<sup>th</sup> ed. Philadelphia:2001:617-618.
2. Houpt P, Storm van Leeuwen JB, Van Den Bergen HA, Intraneural lipofibroma of the median nerve. *J Hand Surg (Am)*. 1989; 14:706
3. Sondergaard G, Mikkelsen S. Fibrolipomatous hamartoma of the median nerve. *J. Hand Surg*. 1987;2:224,
4. Jacob RA. Buchino J J. Lipofibroma of the superficial branch of the radial nerve. *J. Hand Surg (Am)*. 1989;14(4):704-06
5. Bibbo C, Warren AM. Fibrolipomatous hamartoma of nerve. *J Foot Ankle Surg*. 1994;33:64
6. Donley BG, Neel M, Mitias HM. Neural fibrolipoma of the foot: a case report in *Foot Ankle Int*. 1996. Nov, 17(11):712-3Surg,33:64.
7. Akiuse T, Matsumoto K, Yamamoto T, Kizaki T, Fujita I, Yoshiya S, Kurosaka M. Neural fibrolipoma of the superficial peroneal nerve in the ankle: a case report with immunohistochemical analysis in *Pathol Int*. 2002;52(11):730-33.
8. Terzis JK, Daniel RK, Williams HB, Spencer PS. Benign fatty tumors of the peripheral nerves. *Ann. Plast Surg*. 1978;1:193-216.
9. Silverman TA, Enzinger FM, Fibrolipomatous hamartoma of nerve: a clinicopathologic analysis of 26 cases. *Am. J. Surg. Pathol*. 1985;9:7

10. Chatillon CE, Guiot MC, Jacques L. Lipomatous, vascular, and chondromatous benign tumors of the peripheral nerves: Representative cases and review of the literature. *Neurosurg Focus*. 2007;22:75-79
11. Murphey MD, Smith WS, Smith SE, Kransdorf MJ, Temple HT. From the archives of the AFIP. Imaging of musculoskeletal neurogenic tumors: radiologic-pathologic correlation. In *Radiographics*. 1999;19(5):1253-80.
12. De Maeseneer M, Jaovisidha S, Lenchik L, Witte D, Schweitzer ME, Sartoris DJ, Resnick D, Fibrolipomatous hamartoma : MR imaging findings. *Skeletal Radiol*. 1997; 26:155-60.