



International Journal of Medical Research & Health Sciences

www.ijmrhs.com

Volume 3 Issue 1 (Jan- Mar)

Coden: IJMRHS

Copyright ©2013

ISSN: 2319-5886

Received: 29th Sep 2013

Revised: 28th Oct 2013

Accepted: 13th Nov 2013

Case report

SCOLIOSIS CORRECTION IN CHILDREN-ANAESTHETIC CHALLENGE: A CASE REPORT

* Amarjeet D Patil¹, Sivashankar KR², Arpan Sashankar³, Shikha A Malhotra⁴, Nitin Kapoor⁵, Charu Sudan⁶

¹Assistant Professor, ²Professor & Head, ³Assistant Professor, ^{4,5,6}Resident, Department of Anaesthesiology, MGM Medical College and Hospital, Kamothe, Navi Mumbai, India

* Corresponding author email: amarjeetpatil999@yahoo.co.in

ABSTRACT

Kyphoscoliosis is a challenging surgery to surgeons but even more challenging to anaesthesiologist to give anaesthesia and maintain it throughout the surgery and post operative pain relief and ventilation. Here we are describing the case of 3 years old male child weighing 9kg for surgical correction of spine deformity with instrumentation.

Keywords: Scoliosis, Children and Anaesthesia

INTRODUCTION

Scoliosis is defined as a curvature in the vertebral column from side to side and kyphosis is a curvature from anterior to posterior.¹ Kyphoscoliosis can be congenital, idiopathic or postural. Surgical correction is usually attempted from the age of 10. Advances in paediatric anaesthesia and expertise of the surgeons are allowing this correction to be attempted at the very early stage. Positioning of the infant for surgery, gross fluid shifts and manipulation of neural structures pose a challenge to the anaesthesiologist. Surgical correction with instrumentation in a boy of nine kilos is described in this paper.^{2,3}

CASE REPORT

Nine kgs, 3 years, boy was admitted in our tertiary care hospital, MGM Medical College & Hospital, Navi Mumbai, for surgical correction of deformity of spine since one year. Clinical examination revealed no other congenital anomaly and cardiorespiratory system not deranged apart from the positional change. Radiological findings revealed the extent of angulation of the vertebral column in all directions. The child was planned for surgical correction with

instrumentation with complete preparedness for invasive monitoring and replacement of blood and blood products.

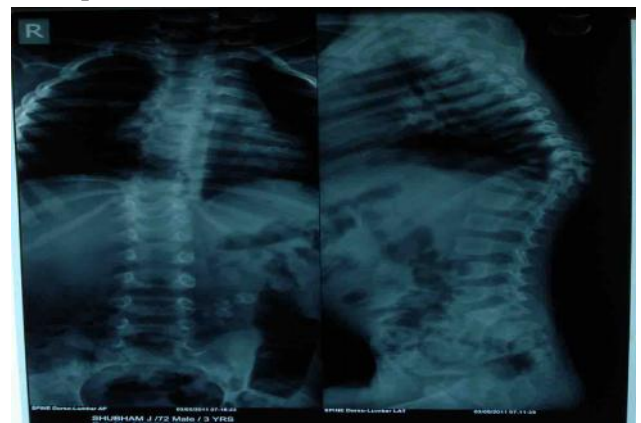

Fig 1: Pre-operative X-ray of patient AP & Lateral views

TECHNIQUE⁴

The infant was assessed, prepared, premedicated as per standard protocol.⁵ Intravenous induction, intubation with non depolarizing blocking agents was resorted to once the peripheral iv line was secured. Central line (Rt internal jugular cannulation 4.5 fg) and

left radial artery cannulated Positioning of the infant for surgery was supplemented by cotton bundles apart from standard bolsters. Proper eye padding given.⁶ Standard monitoring of oxygen saturation, end tidal carbon dioxide (EtCO₂), invasive blood pressure (IBP), central venous pressure (CVP) and urine output was being done, neuromuscular monitoring was not possible because the instrument was defective on that day.⁷

Anaesthesia was maintained with intermittent neuromuscular blocking agents, inhalational anaesthetic and opioid analgesia. We took care to avoid hypothermia by warming mattress, warm fluids.⁸ Surgery was uneventful for 480 minutes.⁹ Elective postoperative mechanical ventilation was done for 24 hours.¹⁰

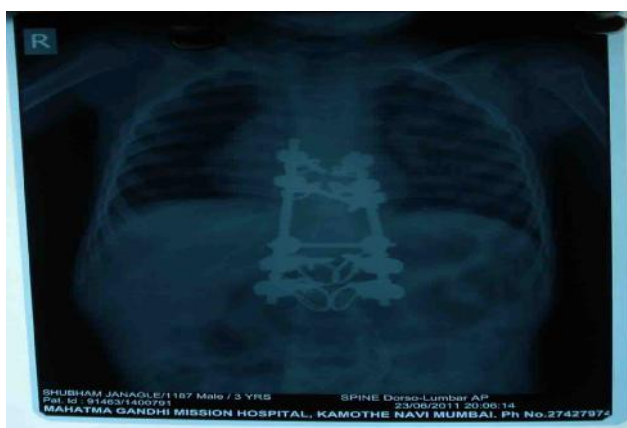


Fig 2: Post operative X-ray AP view

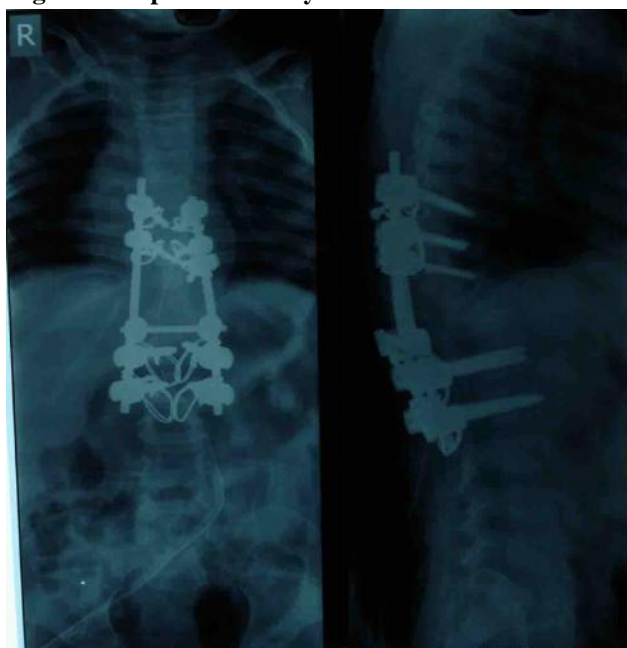

Fig 3: Post operative X-ray AP & Lateral view

DISCUSSION

Very few cases have been reported of infants below 10 kgs undergoing surgical correction and instrumentation of gross Kyphoscoliosis. Positioning of the child should be preferably with 9 poster frame.¹¹ We had resorted to cotton bundles for the same, cannulation of Internal jugular vein and radial artery in children needs experienced hands. Proper monitoring of effects of gross fluid shifts is mandatory along with correction of the same. Monitoring of spinal cord functions could not be done in this surgery. No complications were noticed in the form of brachial plexus injury and ocular changes or air embolism.

CONCLUSION

With clinical experience of the Anaesthesiologist, expertise of the surgeon, surgical correction of kyphoscoliosis even in children is possible now-a-days¹²⁻¹⁴.

ACKNOWLEDGEMENT

We would like to extend our heartfelt gratitude to the Department of Orthopedics, Department of Pediatrics, Radiology and Physiotherapy.

REFERENCES

1. Weinstein SL, Dolan LA, Spratt KF, Peterson KK, SpoonamoreMJ, Ponseti IV. Health and function of patients with untreated idiopathic scoliosis. A 50 year natural history study. *JAMA* 2003; 289:559-67.
2. Michael AE, Davandra Patel. *Contin Educ Anaesth. Crit Care Pain* 2006;6 (1): 13-16.
3. Ogilvie JW, Winter RB, Bradford DS, Lonstein JE, Ogilvie JW, eds. *Historical Aspects of Scoliosis. Moe's Textbook of Scoliosis and other Spinal deformities* 3rd Edition. WB Saunders Company. Philadelphia, USA, 1995; 1-4.
4. Salem MR, Klowden AJ, Gregory GA, ed. *Pediatric Anesthesia. Anesthesia for Orthopedic Surgery* Churchill Livingstone, New York, USA, 2002; 617-61.
5. Standards, Guidelines, Statements and Other Documents. www.asahq.org
6. Myers M, Hamilton SR, Bogosian A, Smith CH, Wagner TA. Visual loss as a complication of

- spine surgery: A review of 37 cases. *Spine* 1997; 22:1325-29.
7. Ramirez N, Richards BS, Warren PD, Williams GR. Complications after posterior spinal fusion in Duchenne's muscular dystrophy. *J Pediatr Orthop* 1997; 17:109-14.
 8. Sessler DI. Mild perioperative hypothermia. *N Engl J Med* 1997; 336:1730-37.
 9. Tsirikos AI, Chang W, Dabney KW, Miller F. Comparison of one stage versus two stage anteroposterior spinal fusion in pediatric patients with cerebral palsy and neuromuscular scoliosis. *Spine* 2003; 28:1300-05.
 10. Rawlins BA, Winter RB, Lonstein JE. Reconstructive spine surgery in pediatric patients with major loss in vital capacity. *J Pediatr Orthop* 1996; 16:284-292.
 11. Winter RB, Lonstein JR, Herkowitz H, Garfin SR, Balderstone RA, Eismont FJ, et al., Juvenile and Adolescent Scoliosis. Rothman-Simeone, *The Spine* 4th Edition. WB Saunders Company, Philadelphia, USA, 1999; 325-72.
 12. Wazeka AN, DiMaio MF, Boachie-Adjei O, Oheneba MD. Outcome of pediatric patients with severe restrictive lung disease following reconstructive spine surgery. *Spine* 2004; 29:528-534
 13. Merola A, Hafer T, Brkaric M. A multicenter study of the outcomes of the surgical treatment of adolescent idiopathic scoliosis using the Scoliosis Research Society (SRS) outcome instrument. *Spine* 2002; 27:2046-2051.
 14. Shapiro G, Green DW, Fatica NS, Boachie-Adjei O. Medical complications in scoliosis surgery. *Curr Opin Pediatr* 2001; 13: 36-41.