



## A 10-Year Retrospective Study on Hydatid Disease in Jordan with Emphasis on the Role of Imaging in Its Diagnosis

Al-Radaideh Ali M<sup>1\*</sup>, Hijjawi Nawal S<sup>2</sup>, Abdelfattah Ali M<sup>2</sup>, Al-Khreisat Mutaz J<sup>2</sup> and Bani-Hani Kamal E<sup>3</sup>

<sup>1</sup>Department of Medical Imaging, Faculty of Allied Health Sciences, The Hashemite University, Zarqa, Jordan

<sup>2</sup> Department of Medical Laboratory Sciences, Faculty of Allied Health Sciences, The Hashemite University, Zarqa, Jordan

<sup>3</sup> Faculty of Medicine, The Hashemite University, Zarqa, Jordan

\*Corresponding e-mail: [ali.radaideh@hu.edu.jo](mailto:ali.radaideh@hu.edu.jo)

### ABSTRACT

**Aim:** To investigate the burden of hydatid disease (HD) on Jordanian population during the past 10 years and highlight the most commonly used imaging modalities for its diagnosis.

**Materials and methods:** Information of 217 HD patients including age, gender, address, organ involved, number and size of hydatid cysts, radiological and histopathological results were recorded from registry offices of four main Jordanian hospitals after receiving the required approvals.

**Results:** The highest number of HD cases was recorded from the central provinces of Jordan; however, most cases were reported from Al-Mafraq governorate. Ultrasound (US) was the most widely used diagnostic tool for HD. The liver was the most affected organ with HD and the age of most of the inspected patients was in the 3rd, 4th, and 5th decades. Single cyst per organ was recorded in 138 of the cases and large hydatid cysts (>5 cm) were observed in 48 cases.

**Conclusions:** Besides the awareness and control measures which are implemented by the Ministry of Health in Jordan to eradicate HD, results of the present study indicated that HD is still regarded as an important public health problem in the country. Imaging plays an essential role in the initial diagnosis of HD but not the classification of the disease. However, the definitive diagnosis is achieved after the surgical removal of hydatid cysts and the confirmation of the presence of the hydatid cyst layers is tested by histopathological techniques. Currently, surgery remains the only available treatment approach for HD in Jordan.

**Keywords:** Ultrasound, computed tomography, cystic echinococcosis, hydatid disease, histopathology, Jordan

### INTRODUCTION

Cystic echinococcosis (CE) or what is popularly known as hydatid disease (HD) is a worldwide zoonosis that is caused by the infection with the larval stage of the *Echinococcus* tapeworms. The two most common forms of HD in humans are the unilocular hydatidosis (caused by *Echinococcus granulosus*) and the alveolar hydatidosis (caused by *Echinococcus multilocularis*) [1,2]. Unilocular hydatidosis has a worldwide distribution especially within communities who raise animals for meat production [3-5]. HD is a popular disease which is endemic in most mediterranean basin including Jordan [5]. Furthermore, CE, which leads to the formation of unilocular hydatid cysts, is the only detected form of HD in Jordan so far [6-9]. Human serve as an accidental intermediate host for the CE. However, numerous other livestock animals, such as sheep, goat, swine, cattle, horses, and camel, can also develop CE. Dogs and other canids act as definitive hosts for *Echinococcus* species and are regarded as the main source of infection. Dogs acquire the infection with *Echinococcus granulosus* adult worms upon eating offals and carcasses of animals (intermediate hosts) containing hydatid cysts which start to shed infective eggs in their faeces [2,11-13]. As a result, human acquire

the infection upon the ingestion of the eggs of *E. granulosus* with contaminated food or water, which eventually develop slowly into hydatid cysts mainly in the liver and lung leading to the eventual pathological damage [3,7-9]. The signs and symptoms of HD are based mainly on the number, size, location, and speed of growth of the cysts inside the internal organs. HD remains asymptomatic for many years until the cysts increase in size and become more than 5 cm in diameter, where they start to squeeze on the infected tissues and, in several occasions, cyst's fluid might spill out causing allergic reactions and/or life-threatening anaphylaxis [13-15].

Imaging procedures such as ultrasound (US), computed tomography (CT) and magnetic resonance imaging (MRI) play a great role in the diagnosis and evaluation of the extent of HD [16,17]. The choice of the most appropriate imaging technique for the proper diagnosis of HD depends on the organ involved and the stage of the disease. US is considered as the best imaging method of choice for the initial diagnosis of HD since it allows cysts categorization into different types according to its nature as; solitary univesicular, solitary multivesicular, solid echogenic mass, multiple univesicular, multiple multivesicular, or collapsed, flattened and calcified [18]. It can define the number, site, dimensions, and viability of the hydatid cysts [19]. The most widely used and standardized classification for hydatid cyst was proposed by the World Health Organization (WHO) in 2001 [20] and based on Gharbi's classification (1981) [21]. The WHO classification system relies on some CE-specific US imaging features which help in the diagnosis, staging and follow-up of CE cysts [20]. In addition, US is considered the preferred tool in monitoring the efficacy of anti-hydatid therapy before and after surgical removal of the hydatid cysts [19,20]. On the other hand, CT scan has high sensitivity and specificity over the US for HD diagnosis [21] and is required in cases where the US proved inadequate due to patient-related difficulties such as obesity, excessive intestinal gas, previous surgery [21-24] and dead or calcified cysts [22,23]. MRI is a useful imaging technique and superior to any other imaging modalities in demonstrating neural involvement [24]. Furthermore, MRI can demonstrate cyst wall defects, cyst contents passage through defected, floating membranes and any irregularities of the cyst rim representing incipient detachment of the membranes [25-27]. The MRI characteristic sign of HD is represented by the low-signal-intensity rim on T2-weighted images "rim sign" [28-30]. The "snake sign" is another typical MRI finding, which represents collapsed membranes due to damaged or degenerated hydatid cyst. Both CT and MRI are very important in the diagnosis and management of HD as they provide a broad knowledge of the lesion size, location, and relations to other structures. CT and MRI-based hydatid cyst classifications were described by Kalovidouris, et al. [31] and von Sinner, et al. [32], respectively. Radiological diagnosis can be further confirmed by several antibody-based immunological assays. The high rates of false negative results of serological tests restrict their confirmatory role [28] especially at early cyst stage (hydatid fluid-filled endocysts) and late stage of involution (solid and wall calcified cysts).

Although several retrospective and case report studies on the incidence of HD in Jordan have been conducted in previous years (Table 1), the last retrospective study was conducted in 2003 and thereafter neither the role of the most appropriate diagnostic imaging techniques employed in this country for HD diagnosis nor the burden of HD among Jordanians have been investigated. Therefore, the main aim of the present study was to follow up on previous work on HD that has been ceased over the past 13 years in order to investigate the present burden of HD among Jordanians and highlight the most commonly used imaging modalities in Jordan for its diagnosis.

### MATERIALS AND METHODS

The present retrospective study was carried out upon accessing the medical records from four main Jordanian hospitals for 217 patients, who underwent surgical removal of hydatid cysts during the past 10 years (from 2005 to 2015). Human ethical approval for this study was issued by the Institutional Review Board at the Hashemite University, Jordan (Ethics permit number: 1500175) in order to access the HD patients records from the following four major

**Table 1** Some previous retrospective studies on hydatid disease in Jordan

Study	Period/years	Number of patients
Yaghan, et al. [16]	1994-2003	65
Al- Qaoud [36]	1994-2000	472
Kamhawi, et al. [35]	1985-1993	676
Amr, et al. [34]	1976-1986	306
Shennak, et al. [9]	1985	63
El-Muhtaseb, et al. [8]	1973-1983	132

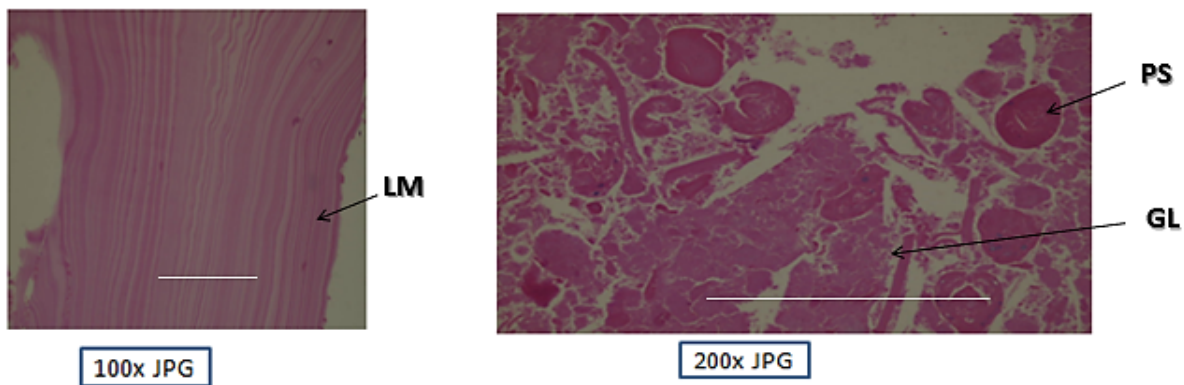
referral Jordanian governmental and private hospitals: Al-Hussein medical City (Royal Medical services), Jordan University Hospital, Prince Hamza Hospital and Specialty Hospital. The collected demographic data of the patients included information on the patient’s age, gender, address, organ/organs involved, the number and size of the hydatid cysts, radiological and histopathological findings.

**RESULTS**

Demographic data were successfully extracted from 217 HD patients who underwent for surgical removal of hydatid cysts and histopathologically confirmed to be infected with the parasite where the presence of typical layers of hydatid cysts (laminated and germinal layers with numerous protoscolices) were confirmed upon taking cross sections from the excised hydatid cysts and stained them with haematoxylin and eosin (Figure 1).

Upon the analysis of the collected data, it was evident that the highest number of HD cases was recorded from the central provinces of the country (108 cases (49.77%)) and among cities; Al-Mafraq area reported the highest number of HD cases (49 cases (22.58%)) (Table 2 and Figure 2). The US and CT images showed that HD cysts were recorded mostly in the liver (128 cases, 59%), followed by the lungs (64 cases, 29.5%), however hydatid cysts can develop in other organs such as spleen (20 cases, 9.2%), brain (2 cases, 0.93%), kidney (2 cases, 0.93%) and neck (1 case, 0.47%). The typical and common appearance of hepatic hydatid cyst on US and CT images are shown in Figures 3 and 4.

Upon analyzing the sex and organ distribution of the HD (Table 3), it was found that HD was recorded in females (130 cases (59.9%)) more than in males (87 cases (40.1%)) on both the US and CT images. Whereas the liver and spleen HD cases were higher in females (81 and 18, respectively) than in males (47 and 2, respectively), the number of lung HD cases were higher in males (35 and 1, respectively) than in females (29 and 1, respectively) and equal numbers of HD cases were recorded in both sexes for the brain and kidney. The age distribution presented in table (4) shows that the majority of the HD patients were in the 3rd, 4th and 5th decades (128 cases, (59%)) with a mean age of  $36.77 \pm 18$  years and age range of 1-90 years. Table 5 summarizes the radiological characteristics of the inspected HD cases and



**Figure 1** Histological cross section of gross specimen showing the different layers of hydatid cyst: Laminated membrane (LM), and germinal layer (GL) with numerous proto scolices (PS). (Haematoxylin and Eosin stain). Scale bar 0.1 mm

**Table 2** The distribution of hydatid disease throughout Jordan

Province	Region	Number of patients	Percentage %
Northern provinces	Irbid (19, 8.75%)	83	38.25%
	Ajlun (6, 2.76%)		
	Jarash (9, 4.14%)		
	Al-Mafraq (49, 22.58%)		
Central provinces	Amman (44, 20.27%)	108	49.77%
	Al-Balqa (32, 14.74%)		
	Ma'daba (11, 5.06%)		
	Al-Zarqa (21, 9.67%)		
Southern provinces	Al-Karak (15, 6.91%)	26	11.98%
	Al-Tafilah (7, 3.22%)		
	Ma'an (4, 1.84%)		

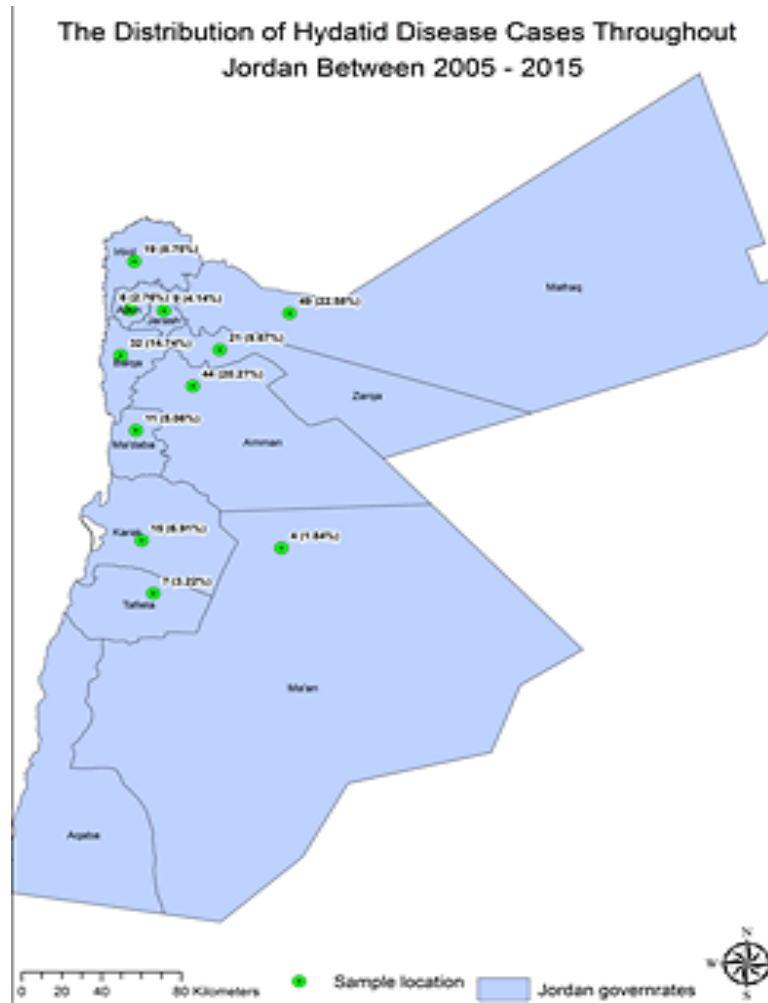


Figure 2 Number and distribution of Hydatid disease cases throughout Jordan which were recorded over the past 10 years

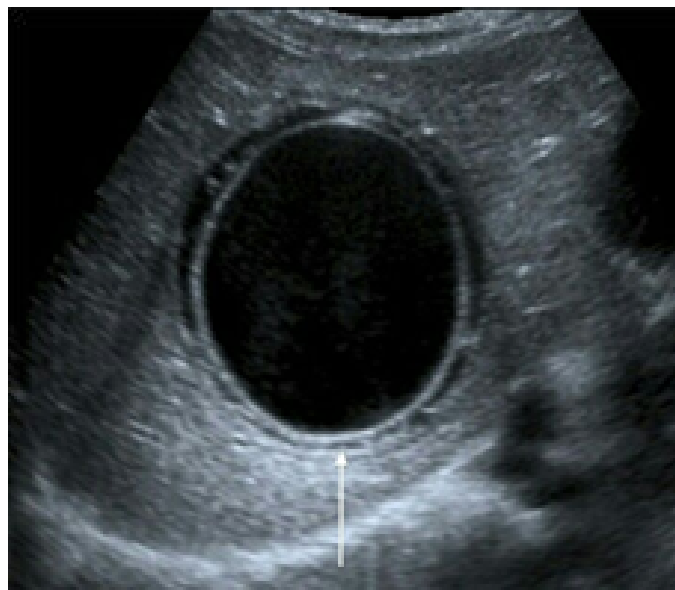

Figure 3 US image shows a large hydatid cyst in the liver of a 37-year-old female

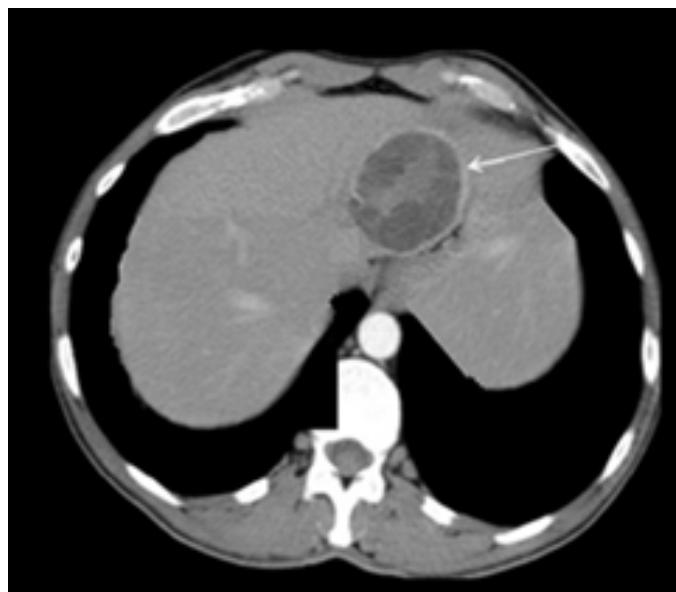


Figure 4 CT image shows a large hydatid cyst in the liver of a 53-year-old female

Table 3 Sex and organ distribution of hydatid disease

Organ	Sex		Total (percentage)
	Male	Female	
Liver	47	81	128 (59%)
Lung	35	29	64 (29.5%)
Spleen	2	18	20 (9.2%)
Brain	1	1	2 (0.93%)
Kidney	1	1	2 (0.93%)
Neck	1	0	1 (0.47)
Total (percentage)	87 (40.1%)	130 (59.9%)	217

Table 4 Age distribution, number, and percentages of hydatid disease cases

Age (years)	Number of cases	Percentages
01-10	15	6.90%
11-20	25	11.52%
21-30	42	19.36%
31-40	45	20.74%
41-50	41	18.90%
51-60	27	12.44%
61-70	13	6%
71-80	6	2.76%
81-90	3	1.38%

shows that the initial diagnosis of the disease was based mainly on imaging techniques in all four hospitals that have been included in the study. While 128 cases (59%) have been diagnosed by US, 89 cases (41%) have been diagnosed using CT. The number of cysts per organ was recorded and summarized in as one cyst (138 cases, 63.6%), two cysts (56 cases, 25.8%), three cysts (18 cases, 8.3%), four cysts (3 cases, 1.4%), five cysts (1 case, 0.46%), and six cysts (1 case, 0.46%) per organ. Figure 5 shows a CT image, on which, multiple unilocular cysts were detected in both lungs of the same patient. No multi-organ cysts were recorded for any of the studied patients.

## DISCUSSION

The whole understanding of the clinical lineaments of HD started in the late 1800's [29] and the earliest four human hydatid disease cases in Jordan were reported in 1966 [6]. Several retrospective and case report studies have been conducted in Jordan indicating that HD is an endemic disease in this country (Table 1). Two of the previous studies are regarded as the most comprehensive ones [30,31]. The first study involved 676 HD cases [30] and the other one involved 472 HD cases [31]. In the first study, an estimated incidence rate of 0.5-8.2 per 100,000 with an overall mean of 2.9 per 100,000 was reported [30]. The other study reported a close annual surgical incidence of 2.3 per 100,000 [31]. In the above two mentioned studies, the most common organ involved in HD was the liver followed by the lung. Few other retrospective studies with a smaller number of patients were conducted all over Jordan [7,8,15,29] (Table 1). Although several comprehensive studies and case reports were published since 1966 in an attempt to highlight the importance of HD in Jordan, however, its exact prevalence in this country is still unclear and requires further investigations. The majority of HD patients have been diagnosed accidentally upon normal abdominal scans since most of the cases are asymptomatic due to the slowly growing nature of the disease (cyst increases in size from 1 cm to 5 cm in diameter per year). About 10% to 20% of the HD cases are diagnosed in patients younger than 16 years and patients become symptomatic if these cysts affect sensitive organs such as the brain or eyes regardless of their sizes [32,33]. However, patients with large hydatid cysts tend to show more obvious symptoms than those with smaller ones [34].

Depending on their radiological appearance on CT and MRI images, hydatid cysts can be classified into four types [31,32]. These include type one (simple cyst with no internal architecture), type two (cyst with daughter cysts and matrix inside), type three (calcified or dead cyst), and type four (ruptured or infected cyst) [31,32]. However, the most widely used and standardized classification for hydatid cyst was proposed by the World Health Organization (WHO) in 2001 [20] and based on Gharbi's classification (1981) [21]. The WHO classification system includes the following categories: cystic lesion (CL), unilocular cystic lesion (or lesions) with uniform anechoic content (without pathognomonic signs); cystic echinococcosis type 1 (CE1), unilocular cysts with uniform anechoic content and with pathognomonic signs (visible cyst wall and 'snowflake' signs); cystic echinococcosis type 2 (CE2), multivesicular, multiseptated cysts; cystic echinococcosis type 3 (CE3), anechoic content with detachment of laminated membrane from the cyst wall visible as floating membrane or as 'water-lily' sign; cystic echinococcosis type 4 (CE4), heterogeneous hypoechoic or hyperechoic degenerative contents (with no daughter cysts present); and cystic echinococcosis type 5 (CE5), cysts are characterized by their thick, calcified, arch shaped walls [20].

In Jordan, the routine diagnosis of the HD is usually based on imaging techniques, which, in some cases, is further

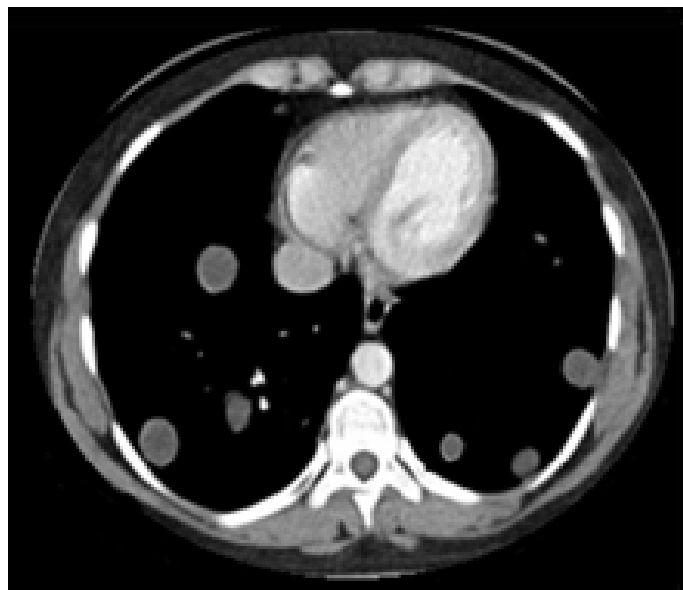

Figure 5 CT image shows multiple unilocular cysts in the lungs of a 26-year-old female

**Table 5 Radiological characteristics of the 217 hydatid cases**

<b>Imaging modality (number of cases)</b>	CT (89)	US (128)
<b>Organs involved (number of cases)</b>	Liver (20)	Liver (26)
	Lung (6)	Lung (9)
	Spleen (4)	Spleen (4)

\* CT (Computed Tomography); US (Ultrasound)

**Table 6 Number of hydatid lesions per organ as detected on CT and US images for the liver, lung, spleen, brain, kidney, and neck**

Number of lesions/organ	CT	US	Total
1	54	84	138 Liver (74); Lung (45); Spleen (14); Brain (2); Kidney (2); Neck (1)
2	26	30	56 Liver (37); Lung (14); Spleen (5)
3	5	13	18 Liver (14); Lung (3); Spleen (1)
4	3	0	3 Liver (2); Lung (1)
5	0	1	1 Liver (1)
6	1	0	1 Lung (1)

\* CT (Computed Tomography); US (Ultrasound)

confirmed by various immunodiagnostic methods. In the present study, US was used more frequently than CT for the diagnosis of HD and could show different cases with multiple lesions per organ more than CT. Although some previous studies found that CT scan is a good technique and superior to US for the diagnosis of HD in the lung and liver due to its higher detection ability of calcified or infected cysts than US [24], the records from this retrospective study showed that more lung and liver hydatid cases (single or multiple lesions per organ) were detected on US than on CT. The availability, low cost, and the lack of ionizing radiations make the US the cornerstone of HD diagnosis in Jordan. However, in Jordan surgeons do not rely on imaging for HD classification and intervene based on cyst presence rather than its classification. So, the definitive diagnosis of HD is always confirmed after the surgical removal of the hydatid cysts, when biopsies are taken to provide a comprehensive histopathological examination for the presence of the typical cyst layers and the larval stages (protoscolices) of the parasite [2,21,34]. Figure 1 shows light microscopic images (photomicrographs) for the typical layers of a liver hydatid cyst (laminated and germinal layer with protoscolices) and thus histopathologically confirming the diagnosis as HD.

The present study showed that cysts in most HD patients (128 cases, 59%) were reported to occur in the liver followed by the lungs (64 cases, 29.5%). These findings were consistent with many previous studies which indicated that these two organs are the primary sites for the development of hydatid cysts [7,8,15,29-31]. While the liver is the primary filter in the human body, the lung is thought to be the second filter [32]. In addition, the development of the cysts was also reported in different organs other than the liver and lungs such as the spleen, brain, kidneys, and neck. These findings were also reported in some other previous studies and reports [21,35-45]. In one study, hydatid cyst was reported to occur in the pancreas of a 33-year-old male patient [9].

Single hydatid cyst per organ tends to be dominant over the multiple cysts per organ. This was observed in the present study where 63.6% of the hydatid cysts were recorded to occur as a single cyst per organ and only 36.4% of these cysts were reported to occur in two, three, four, five or six cysts per organ. These results support other previous studies which indicated that primary cysts are predominately solitary in nature [46,47]. No multi-organ cysts were recorded for any of the studied patients.

In the present study, the analysis of the geographical distribution of CE cases and their residential origin throughout Jordan showed that the highest number of HD cases was recorded from the central provinces of the country (108 cases (49.77%)) and among cities, Al-Mafraq area reported the highest prevalence (49 cases (22.58%)). Al-Mafraq



city is famous for agricultural and animal husbandry and there are a huge number of dogs (the definitive host of the parasitic worm) that come close to homes and accompany farmers and shepherds. Therefore, human in this area has a closer contact with livestock and dogs since most of them raise sheep for meat and milk production. Moreover, it was observed that the number of stray dogs has increased significantly over the past 5-6 years (personnel observation) and this could be due to the location of Al-Mafraq city on the border with Syria from which a huge number of dogs fled and reside in this area due to the active war in Syria [48-50].

The reported results in this study showed that HD was more prevalent in females 130 (59.9%) than in males 87 (40.1%). The high female to male ratio among HD cases supports findings in many other previous retrospective studies which were conducted in Jordan so far [29-31]. While it was more common among women above age 20 years, HD was found to occur more in males under age 20 years. This might be explained by the fact that young males in Jordan have more outdoor activities during childhood compared to females and this might lead to an increase in the probability of exposure to the infective stage (eggs) of the parasite. However, after the age of 20 years, women in rural areas of Jordan become engaged with a lot of household and farm responsibilities, such as milking animals, weeding and fencing, livestock care, cultivating and harvesting crops and may be more exposed to the infective stage. Most of the men in Jordan above the age of 20, on the other hand, are involved in military or government work and actually become at lower risk to get infected with HD than females [34]. Moreover, above age 20, females access health care centres more frequently such as during pregnancy period and thus they have more chances to receive an accidental diagnosis. While the occupation of the patients was not documented during the present study, previous studies found that most of the women suffering from HD were found to be unemployed (housewife) and engaged with a lot of household activities, which could have been contributed to the high HD prevalence [15,29].

#### CONCLUSION

Imaging plays a great role in the diagnosis and classification of the HD worldwide. However, in Jordan, imaging (mainly US and CT) is used only in the diagnosis of HD and has not been widely implemented in its classification yet although it is a popular and endemic disease in the country. So, the definitive diagnosis of HD is always confirmed after the surgical removal of the hydatid cysts using histopathology.

#### CONFLICT OF INTEREST

The authors have no conflicts of interest to declare.

#### ACKNOWLEDGEMENT

This research did not receive any specific grant from funding agencies in the public, commercial, or not-for-profit sectors.

#### REFERENCES

- [1] McManus, D. P. "Current status of the genetics and molecular taxonomy of *Echinococcus* species." *Parasitology* 140.13 (2013): 1617-1623.
- [2] Moro, Pedro, and Peter M. Schantz. "Echinococcosis: A review." *International Journal of Infectious Diseases* 13.2 (2009): 125-133.
- [3] Thompson, R. C. A., and McManus, D. P. "Aetiology: Parasites and life-cycles". WHO/OIE Manual on echinococcosis in humans and animals: A Public Health Problem Global Concern. Paris; 2001. p. 1-19.
- [4] Zhang, Wenbao, and Donald P. McManus. "Recent advances in the immunology and diagnosis of echinococcosis." *FEMS Immunology and Medical Microbiology* 47.1 (2006): 24-41.
- [5] Ito, Akira, et al. "Cystic echinococcoses in Mongolia: Molecular identification, serology and risk factors." *PLoS Negl Trop Dis* 8.6 (2014): e2937.
- [6] Budke, Christine M. A., Clinton White Jr, and Hector H. Garcia. "Zoonotic larval cestode infections: Neglected, neglected tropical diseases?." *PLoS Negl Trop Dis* 3.2 (2009): e319.
- [7] Khoury, S., and Kamhaway A. "Hydatid Disease." *Jordan Medical Journal* 1 (1966): 8-14.
- [8] El-Muhtaseb H. H. "Surgical management of hydatid cyst of liver: A retrospective study of 75 cases." *Jordan Medical Journal* 18 (1984): 35-46.



- [9] Shennak, M. M., et al. "Patterns of hepatomegaly in Jordanians: A prospective study of 800 cases." *Annals of Tropical Medicine and Parasitology* 79.4 (1985): 443-448.
- [10] Heis, H. A., and Bani-Hani, K.E., and Elheis M. A. "Primary hydatid cyst of the pancreas." *Acta Chirurgica Belgica* 109.5 (2009): 626-628.
- [11] Pawlowski, Z. S., et al. "Echinococcosis in humans: Clinical aspects, diagnosis and treatment." *WHO/OIE manual on echinococcosis in humans and animals: A public health problem of global concern* (2001): 20-71.
- [12] Eckert, Johannes, and Peter Deplazes. "Biological, epidemiological, and clinical aspects of echinococcosis, a zoonosis of increasing concern." *Clinical microbiology reviews* 17.1 (2004): 107-135.
- [13] Bukte, Y., et al. "Cerebral hydatid disease: CT and MR imaging findings." *Swiss medical weekly* 134 (2004): 459-467.
- [14] Cox, Frank E. G. "History of human parasitology." *Clinical microbiology reviews* 15.4 (2002): 595-612.
- [15] Yaghan, Rami J., Kamal E. Bani-Hani, and Hussein A. Heis. "The clinical and epidemiological features of hydatid disease in Northern Jordan." *Saudi medical journal* 25.7 (2004): 886-889.
- [16] Yaghan, Rami, et al. "Is fear of anaphylactic shock discouraging surgeons from more widely adopting percutaneous and laparoscopic techniques in the treatment of liver hydatid cyst?." *The American journal of surgery* 187.4 (2004): 533-537.
- [17] Moro, Pedro L., et al. "Screening for cystic echinococcosis in an endemic region of Peru using portable ultrasonography and the enzyme-linked immunoelectrotransfer blot (EITB) assay." *Parasitology research* 96.4 (2005): 242-246.
- [18] Giri, Sidhartha, and Subhash Chandra Parija. "A review on diagnostic and preventive aspects of cystic echinococcosis and human cysticercosis." *Tropical parasitology* 2.2 (2012): 99.
- [19] Lewall, D. B. "Hydatid disease: Biology, pathology, imaging and classification." *Clinical radiology* 53.12 (1998): 863-874.
- [20] WHO Informal Working Group. "International classification of ultrasound images in cystic echinococcosis for application in clinical and field epidemiological settings." *Acta tropica* 85.2 (2003): 253-261.
- [21] Gharbi, Hassen A., et al. "Ultrasound examination of the hydatid liver." *Radiology* 139.2 (1981): 459-463.
- [22] Scherer, Kurt, et al. "Differential diagnosis and management of a recurrent hepatic cyst: A case report and review of literature." *Journal of general internal medicine* 24.10 (2009): 1161-1165.
- [23] Hosch, W., et al. "Imaging methods in the diagnosis and therapy of cystic echinococcosis." *RoFo: Advances in X-Ray Radiation and Nuclear Medicine* 176.5 (2004): 679-687.
- [24] Polat, Pinar, et al. "Hydatid Disease from Head to Toe 1." *Radiographics* 23.2 (2003): 475-494.
- [25] Rozanes, Izzet, et al. "Cystic echinococcal liver disease: New insights into an old disease and an algorithm for therapy planning." *Cardiovascular and interventional radiology* 30.6 (2007): 1112-1116.
- [26] Mortelé, Koenraad J., and Pablo R. Ros. "Cystic focal liver lesions in the adult: Differential CT and MR imaging features 1." *Radiographics* 21.4 (2001): 895-910.
- [27] Pedrosa, Iván, et al. "Hydatid Disease: Radiologic and Pathologic Features and Complications 1: (CME available in print version and on RSNA Link)." *Radiographics* 20.3 (2000): 795-817.
- [28] Katranci, N., et al. "Correlative CT, MRI and histological findings of hepatic *Echinococcus alveolaris*: A case report." *Computerized medical imaging and graphics* 23.3 (1999): 155-159.
- [29] Vilgrain, Valérie. "Cystic lesions of the liver." *Clinical and biological gastroenterology* 25 (2001): B167-B177.
- [30] Kodama, Yoshihisa, et al. "Alveolar Echinococcosis: MR Findings in the Liver 1." *Radiology* 228.1 (2003): 172-177.
- [31] Kalovidouris, A., et al. "CT characterization of multivesicular hydatid cysts." *Journal of computer assisted tomography* 10.3 (1985): 428-431.
- [32] von Sinner, Walther, et al. "MR imaging in hydatid disease." *AJR. American journal of roentgenology* 157.4 (1991): 741-745.
- [33] Brunetti, Enrico, Hector H. Garcia, and Thomas Junghans. "Cystic echinococcosis: Chronic, complex, and still neglected." *PLoS Negl Trop Dis* 5.7 (2011): e1146.
- [34] Amr, S. S., et al. "Hydatidosis in Jordan: An epidemiological study of 306 cases." *Annals of Tropical Medicine and Parasitology* 88.6 (1994): 623-627.
- [35] Kamhawi, S. "A retrospective study of human cystic echinococcosis in Jordan." *Annals of Tropical Medicine and*

*Parasitology* 89.4 (1995): 409-414.

- [36] Al-Qaoud, Khaled M., Philip S. Craig, and Sami K. Abdel-Hafez. "Retrospective surgical incidence and case distribution of cystic echinococcosis in Jordan between 1994 and 2000." *Acta tropica* 87.2 (2003): 207-214.
- [37] Al-Barwari S. E., Saeed I. S., Khalid W. A-HKI. "Human Hydatidosis in Arbil, N. Iraq." *Medical Journal of Islamic World Academy of Sciences* 4 (1991): 330-335.
- [38] Rojas, Cristian A. Alvarez, Thomas Romig, and Marshall W. Lightowlers. "Echinococcus granulosus sensu lato genotypes infecting humans: Review of current knowledge." *International Journal for Parasitology* 44.1 (2014): 9-18.
- [39] Kammerer, W. S., and Schantz P. M. "Echinococcal disease." *Infectious disease clinics of North America* 7.3 (1993): 605-618.
- [40] Malik, Ajaz A., et al. "Primary splenic hydatidosis." *Indian Journal of Gastroenterology* 30.4 (2011): 175.
- [41] Kireşi, D. A., et al. "Uncommon locations of hydatid cysts." *Acta Radiologica* 44.6 (2003): 622-636.
- [42] Rasheed, Khalid, Showkat Ali Zargar, and Ajaz Ahmed Telwani. "Hydatid cyst of spleen: A diagnostic challenge." *North American journal of medical sciences* 5.1 (2013): 10.
- [43] Ali, Mumtaz, Khalid Mahmood, and Pervez Khan. "Hydatid cysts of the brain." *J Ayub Med Coll Abbottabad* 21.3 (2009): 152-4.
- [44] Ishimitsu, David N., et al. "Renal Hydatid Disease 1." *Radiographics* 30.2 (2010): 334-337.
- [45] Fazeli, Faramarz, et al. "Isolated hydatid cyst of kidney." *Urology* 73.5 (2009): 999-1001.
- [46] Zmerli, Saadeddine M. D., et al. "Hydatid cyst of the kidney: Diagnosis and treatment." *World journal of surgery* 25.1 (2001): 68-74.
- [47] Hmidi, M., et al. "Isolated hydatid cyst of the neck: An unusual site." *European annals of otorhinolaryngology, head and neck diseases* 129.2 (2012): 108-110.
- [48] Chakrabarti, Indranil, and Bidyut Krishna Goswami. "Primary hydatid cyst of the neck diagnosed by aspiration cytology." *Tropical parasitology* 2.2 (2012): 127.
- [49] McManus, D. P. "Zhang w, Li J, Bartley PB. "Echinococcosis. *Lancet* 362 (2003): 1295-304.
- [50] Akther, J., Najnin Khanam, and Siddharth Rao. "Clinico epidemiological profile of hydatid diseases in central India, a retrospective and prospective study." *Int J Biol Med Res* 2.3 (2011): 603-606.