



# International Journal of Medical Research & Health Sciences

[www.ijmrhs.com](http://www.ijmrhs.com)

Volume 3 Issue 1(Jan- Mar)

Coden: IJMRHS

Copyright ©2013

ISSN: 2319-5886

Received: 29<sup>th</sup> Oct 2013

Revised: 24<sup>th</sup> Nov 2013

Accepted: 6<sup>th</sup> Dec 2013

Case report

## DELTO-PECTORAL FLAPS FOR SECONDARY DEFECTS FOLLOWING EXCISION OF RECURRENT PAROTID TUMORS: CASE SERIES

\*Adedeji Taiwo O<sup>1</sup>, Tobhi James E<sup>1</sup>, Olaosun Adedayo O<sup>1</sup>, Oseni Oyeniran G<sup>2</sup>, Idowu Julius A<sup>1</sup>, Olaitan Peter B<sup>2</sup>

<sup>1</sup>Department of Ear Nose and Throat, Ladoke akintola University of Technology Teaching Hospital, Osogbo

<sup>2</sup>Department of Surgery, Ladoke akintola University of Technology Teaching Hospital, Osogbo

\*Corresponding author email: [adedejitaiwo2003@yahoo.com](mailto:adedejitaiwo2003@yahoo.com)

### ABSTRACT

**Background:** Extensive infiltration of the skin by parotid gland tumors often lead to the surgeon seeking various options that will lead to good cosmetic appearance and reduced donor site morbidity. **Materials and Methods:** This is a report of two patients with extensively enlarged parotid tumors with associated skin loss and depth that was difficult to close. Consent/permission was obtained from the patients. The case notes of the patients were reviewed and it shows that apart from local tissues and skin grafts, delto-pectoral flaps could come handy. Outcome is reported in this report. **Results:** Two patients who had a deltopectoral flap cover of their defects following excision of huge parotid tumors involving the infiltration of the overlying skin are reported in this study. There was good aesthetic outcome with minimal and acceptable donor site morbidity. **Conclusion:** Delto-pectoral flaps should be considered an option in covering defects following parotid tumour excision.

**Keywords:** Recurrent parotid tumours, Delto-pectoral flaps, Secondary defects, Cosmesis

### INTRODUCTION

Parotid gland tumors are not common.<sup>1-3</sup> Generally, salivary gland tumors represent about 1-3% of head and neck tumours.<sup>2</sup> In our environment, it constitutes 1.7% of head and neck tumours.<sup>3</sup> Seventy eight to eighty percent of parotid tumours are benign.<sup>2, 3</sup> Parotid tumours elicit considerable medical interest because of their multifaceted clinical presentation, varied histological appearances and the associated difficulties in predicting their prognosis.<sup>1,3</sup> In most cases, therapy consists of parotidectomy and adjuvant therapy – mainly radiotherapy which is reserved for cases with malignancies.<sup>2</sup> Surgical intervention varies from limited excision to extensive parotidectomy with facial nerve sacrifice with or without neck dissection.<sup>2</sup> Factors that influence surgical therapies include facial nerve invasion, tumour extension, histological characteristics and positive limits of the tumor.<sup>2</sup>

The recurrent parotid gland tumor is a challenge to both the patient and the surgeon. Factors responsible for tumor recurrence include histological grade, extent of the tumour, invasion of adjacent structures and poor surgical technique. Recurrence is more common in malignant tumors<sup>4</sup> but in pleomorphic adenoma (a benign tumour), if the capsule ruptured during removal, tumour may implant and cause recurrence.<sup>4</sup> Management of recurrent parotid tumour is challenging.<sup>4</sup> There is a need for wide surgical excision<sup>4</sup> and facial nerve as well as the surrounding soft tissues including skin sacrifices is inevitable. Wide defects are therefore produced necessitating a flap cover or a skin graft. The significant depression created by complete tumour excision is a source of concern for the patient about cosmesis and challenge to the doctor about its closure.

Various options available for repairing the defect include fat grafts, sternocleidomastoid muscle rotation flaps, cellular dermal graft and free vascularized facial graft.<sup>4</sup> The deltopectoral flap is a useful, reliable and versatile regional flap that can be used in selected circumstances for major head and neck reconstruction.<sup>5</sup> This article reports two cases of recurrent parotid gland tumours that were managed by the use of deltopectoral flaps in repairing the defects created following wide surgical excision.

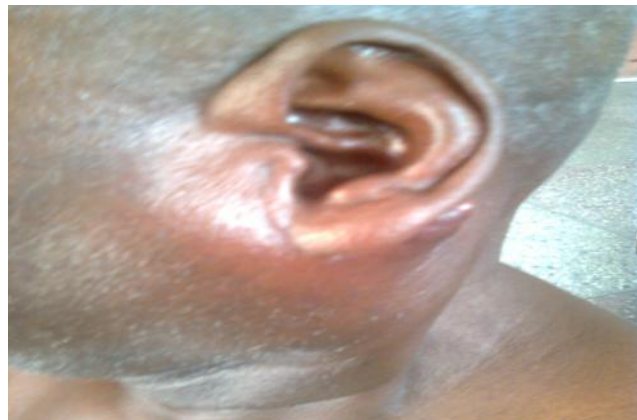### CASE NO 1

A.I. was a 69yr old male Nigerian referred from a private hospital on account of left sided parotid swelling. Progressive left sided parotid swelling noticed about a year prior to presentation. No associated swelling in other parts of the body, no pain and no facial weakness. Examination at presentation showed left sided parotid swelling which measured 6cm x 8cm in its widest dimension. It was firm, non tender with no associated parapharyngeal / oropharyngeal extension and no facial nerve involvement.

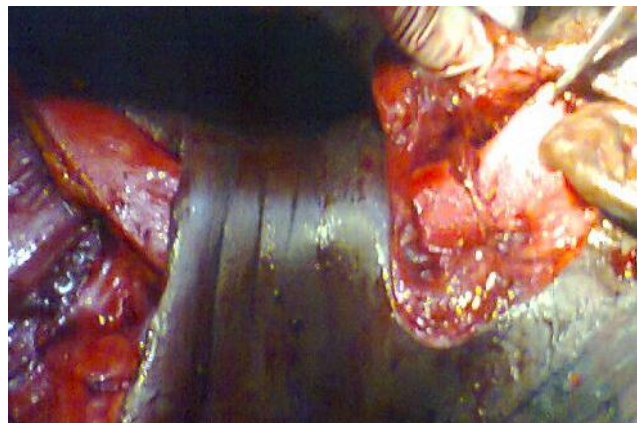
Full blood count, electrolyte and urea and chest radiograph were normal. An ultrasound revealed a cystic mass 4.5cm x 4.7cm in widest dimension. Fine needle aspiration for cytology suggested a benign lesion. Patient had superficial parotidectomy under general anesthesia. Findings at surgery were a cystic mass about 6x6cm which contained sero-sanguinous fluid. Patient was noticed to have developed House and Brachman grade II facial palsy. Histology of the tumour showed adenoid cystic carcinoma on account of which he was referred for radiotherapy and discharged to clinic but was lost to follow up.

He however re-presented two years later on account of 2 months history of recurrent parotid swelling with associated pain and worsening of facial weakness. Examination revealed 8cm x8cm left parotid swelling, firm, non tender and no differential warmth. There was grade III facial palsy. Full blood count, electrolyte and urea, chest radiograph and clotting profile were normal. He had a total parotidectomy. Operative findings were tumour with a cystic cavity that had infiltrated the root of zygoma, facial nerve, posterior wall of external auditory canal and ramus of the mandible. There was a big cavity of about 6 cm depth created. A deltopectoral flap was then designed and raised and de-epithelialised and the distal part turned

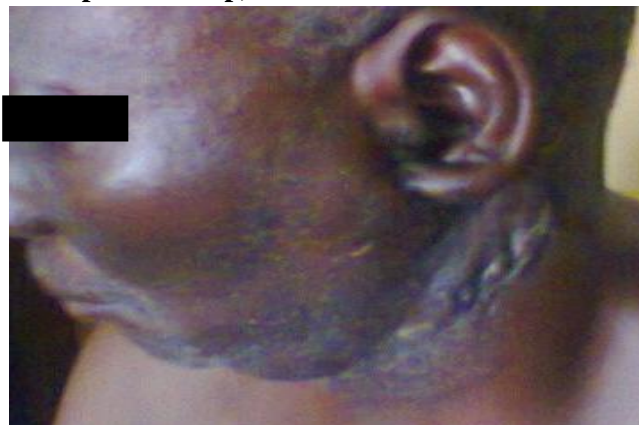over to fill the defect. This was transferred under the skin of the lateral neck. The result was functionally and cosmetically accepted by the patient.



**Fig 1: Huge left parotid tumour infiltrating the skin and ear lobule.**



**Fig 2: Case 1 at surgery (filling the defect with delto-pectoral flap)**

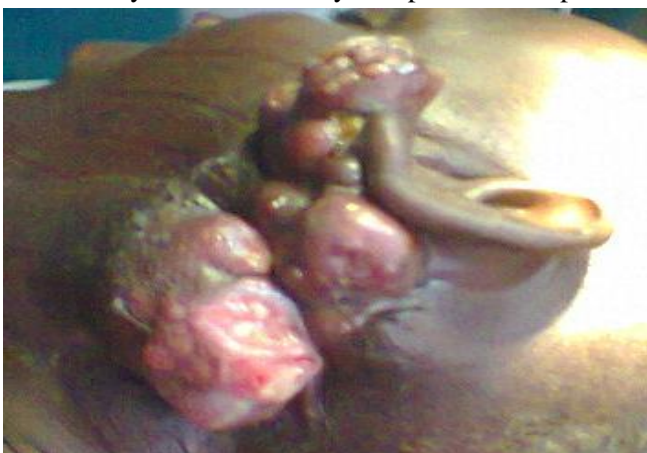

**Fig 3: Post operative appearance**

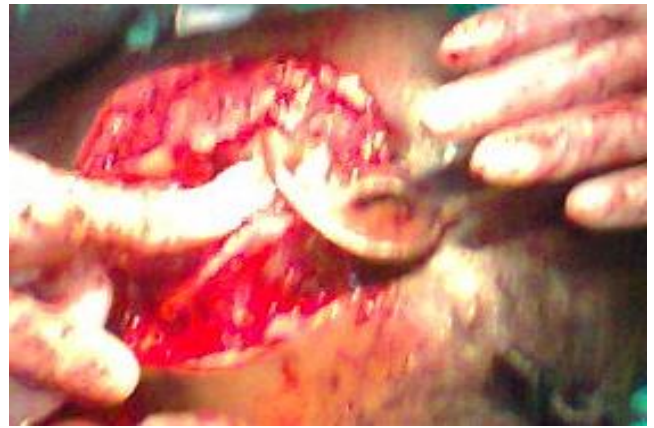### CASE NO 2

A 73yr old widow who presented on account of left sided progressive parotid swelling of five years duration. No associated swelling in other part of the body, no history of pain, trauma or facial weakness and no alteration in the size of the tumour during food intake. Examination revealed an elderly woman with

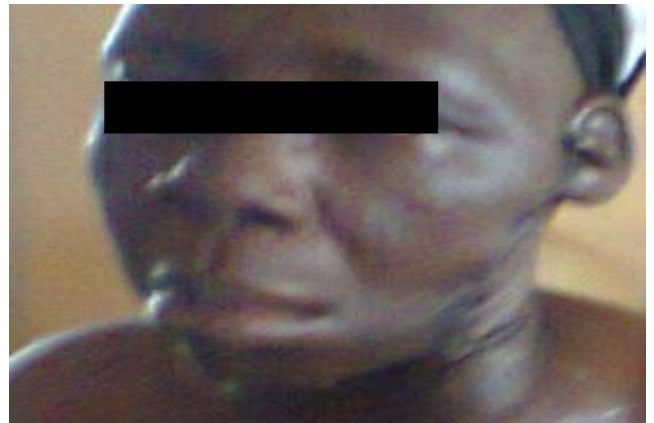12x 11cm left sided parotid mass, firm, non tender and no differential warmth. Full blood count, electrolyte and urea and chest radiograph were normal, electrocardiograph showed left ventricular hypertrophy, neck ultrasound revealed a non homogenous mass with multi-septated cystic masses measuring 10x20mm. Fine needle aspiration for cytology was suggestive of pleomorphic adenoma. She had superficial parotidectomy. Findings at surgery were multi-nodular cystic mass about 25x18cm in its widest dimension. Histology of the tumour showed adenoid cystic carcinoma on account of which she had 54 cGy of radiotherapy. Three years later, patient presented with 6 months history of recurrence. The recurrence was associated with pain, facial weakness, and ulceration and bleeding. Examination revealed an elderly woman with a left parotid mass about 16x8cm in widest dimension which had involved lobule of the ear with a central area of ulceration. Full blood count, electrolyte and urea, and chest radiograph were normal. She had total parotidectomy. Operative findings were multi-nodular masses which had invaded the lobule of the ear and infiltrated the branches of the facial nerve and associated facial weakness. (Fig 4). A wide defect of 10 x 12cm) was created. (Fig 5). Delto-pectoral flap of 24cm length and 8cm width was designed, raised and partly de-epithelialised. It was transferred by tunneling subcutaneously into the defect. It covered the defect completely and healed perfectly. The result was functionally and aesthetically acceptable to the patient



**Fig 4: Extensive recurrent left parotid tumor infiltrating the skin and ear lobule**



**Fig 5: Defect after excision**



**Fig 6: Postoperative appearance of case 2.**

## DISCUSSION

The delto-pectoral flap remains a useful, reliable, and versatile regional flap that can be used alone or in combination with other flaps in selected circumstances for major head and neck reconstruction<sup>5</sup>. It has provided an excellent source of thin and pliable tissue that form appropriate source of donor tissue for reconstruction of limited defects of the pharynx, esophagus, and skin of the neck<sup>6</sup>. The flap has become the most commonly used pedicle regional flap for head and neck reconstruction while providing coverage for most defects of the head and neck from the scalp and skull base to the cervical region and hypopharynx<sup>7</sup>. It continues to play an important role in head and neck reconstruction, reflecting its versatility, reliability, and ease of harvest<sup>7</sup>. The current reports show the versatility of this flap in covering secondary defects from parotidectomy especially in our environment where patients present rather late with tumours that may leave a defect that may not close directly. While Microvascular procedure might have given a better result, facility for this is often not available in most developing countries. This flap therefore comes handy in managing this difficult and extensive defect

especially with the attending cosmetic problem that might arise following the use of inappropriate tissue for the closure.

Head and neck surgeries present unique challenges because of the variety of functions that head and neck are responsible for, including speech, swallowing, sensation, oral continence, airway protection and facial expression. Deformities of the head and neck region can have devastating effects on the appearance and function of the patient and are among the most disabling and socially isolating defects with significant impact on the patient's quality of life. Reconstruction of such defects continues to be an extremely demanding challenge for surgeons who aim to restore form and function with minimal surgical morbidity. These reconstructive surgeries must always be performed in a way that preserves these functions as much as possible. The surgery may be done to restore function, improve cosmetic appearance, or a combination of both.

In the cases presented here, both function and aesthesis were preserved with the flaps-one covering the wide defect smoothly and the other occluding a depth created by the excision of the tumors.

Gardiner et al.<sup>8</sup> reported three cases of recurrent head and neck carcinoma viewed as challenging reconstructive problems because of the extent of the extirpative surgery necessary and the substantial risk of complications that would be associated with previous treatment techniques. They showed that myocutaneous flaps were quite versatile and useful in head and neck reconstructive process<sup>8</sup>. Hurvitz et al.<sup>9</sup> reported that although defects of the head and neck region present a challenge, successful cosmetic and functional results have been achieved with both local and free tissue flaps.

In the first of the cases presented in this article, delto-pectoral flap was designed, raised and de-epithelialised. It was transferred by tunneling subcutaneously into the defect to fill the cavity created while in the second case, the flap with 24cm by 8cm was designed, raised and partly de-epithelialised. It covered the defect completely and healed perfectly. Both results were functionally and aesthetically acceptable to the patients. Delto- pectoral flap is therefore useful in the reconstruction of defects and restoration of cosmetic value to the patients following surgical excision of recurrent parotid tumours.

While the flap functions effectively for aesthesis and function, the limitation of the flap is in the fact that it was bulky and needed to be divided secondarily to remove the bulkiness on the side of the neck in one of the patients. This was in a woman with thick subcutaneous fat. The second problem arose as a result of the fact that the secondary defect was closed directly and this led to about 2-3cm lift of the ipsilateral breast compared to the contralateral side. Although the 73 year old woman was satisfied and did not bother about the disparity in the breasts as a result of the flaps, caution is suggested in raising these flaps in women. Indeed, this problem of lift and the bulkiness that may need a second procedure must always be explained to the patients. Deltopectoral flaps are therefore part of the armamentaria that can be considered for parotidectomy defects.

## CONCLUSION

Delto-pectoral flaps should be considered an option in covering defects following parotid tumour excision. It is useful in the reconstruction of defects, restoration of cosmetic value to the patients with minimal and acceptable donor site morbidity.

## REFERENCES

1. Somefun OA, Oyeneyin JO, Abdulkarrem FB, da Lilly- Tariah OB, Nimkur LT, Esan OO. Surgery of parotid gland tumours in Lagos: a 12 year review. *Niger Postgrad Med J.* 2007; 14(1): 72-75.
2. Mag A, Cotulbea S, Lupescu S et al. Parotid Gland Tumours. *J Exp Med Surg Resear.* 2010; 4: 259-263.
3. Nzegwu MA, Ngozi NR, Ugochukwu AI et al. A Review of Salivary Gland Neoplasm in Eastern Nigeria for A Five- Year Period from January 1, 2000 to December 31<sup>st</sup> 2004. *Adv in Bioresear* 2011; 2(1): 28 – 32
4. Carrol WR, Morgan CE. Diseases of the Salivary Glands. In Ballenger's Otorhinolaryngology Head and Neck Surgery, sixteenth edition (Snow JB, Ballenger JJ eds) BC Decker Inc. Hamilton, Ontario, 2003; 1441 – 1454.
5. Gilas T, Sako K, Razack MS et al. Major Head and neck reconstruction using deltopectoral flap. A 20 year experience. *Am J Surg* 1986; 152(4): 430 – 434.
6. Mortensen M, Genden EM, Role of the island deltopectoral flap in contemporary head and neck

reconstruction. *Ann Otol Rhinol Laryngol.* 2006 ;115(5):361-364

7. Yang JY, Rosen MR, Keane WM. Flaps and Grafts in the Head and Neck. In Ballenger's Otorhinolaryngology Head and Neck Surgery, sixteenth edition (Snow JB, Ballenger JJ eds) BC Decker Inc. Hamilton, Ontario, 2003; 972- 996.
8. Gardiner LJ, Ariyan S, Pillsbury HC. Myocutaneous flaps for challenging problems in head and neck reconstruction. *Arch Otolaryngol.* 1983; 109(6): 396- 399.
9. Hurvitz KA, Kobayashi M, Evans GR. Current options in head and neck reconstruction. *Plast. Reconstr. Surg.* 2006; 118(5):122e-133e.