



# International Journal of Medical Research & Health Sciences

[www.ijmrhs.com](http://www.ijmrhs.com)

Volume 2 Issue 4 Oct - Dec

Coden: IJMRHS

Copyright ©2013

ISSN: 2319-5886

Received: 24<sup>th</sup> Aug 2013

Revised: 15<sup>th</sup> Sep 2013

Accepted: 27<sup>th</sup> Sep 2013

Case report

## MECKEL'S DIVERTICULUM SIX CASE REPORTS OUR EXPERIENCE AND REVIEW OF LITERATURE

\*Meena H. Shaikh, Khilchand Bhangale, Swapnil Kadam, Shantanu Pawar, Tanmay Bhavthankar

Department of General Surgery, Rural Medical College, Pravara Institute of Medical Sciences (DU), Loni, Ahmednagar, Maharashtra, India

\*Corresponding author email: drmeena15@yahoo.com

### ABSTRACT

A Meckel's diverticulum, a true congenital diverticulum, a vestigial remnant. It connects the yolk sac to the small intestine in the early embryonic life. It remains without symptoms. In the children symptoms occur below 2 years. It may contain heterotopic gastric, pancreatic tissue. Presentation can include gastrointestinal bleeding, obstruction, perforation, and volvulus. Because of this wide range of clinical scenarios it is important for a clinician to have a high index of suspicion to prevent significant complications. Investigations like Ultrasonography, Computed tomography (CT scans) and Technetium 99m pertechnate scan helps in diagnosis Treatment is surgical. We are presenting the management of the six cases supported by a review of the literature. The five patients presented with complications and needed emergency operation. This is from the rural set up where the advance facilities are limited. The knowledge of its anatomical and patho-physiological properties is essential to deal with such complications.

**Keywords:** Meckel's Diverticulum, Volvulus, Perforation, Gangreen.

### INTRODUCTION

According to Dr Charles Mayo, a Meckel's diverticulum is frequently suspected, often sought for and seldom found.<sup>1</sup> An accepted incident of Meckel's diverticulum is 1 to 3 percent. There are many complications related to Meckel's diverticula. It is difficult to diagnose Meckel's diverticulum clinically and by modern imaging technique. Depending on the type of the anomaly patients may be completely symptom free or may present with the complications with the chronic abdominal pain. The presentation in

six patients in the present case report is different and created diagnostic dilemma. Meckel's diverticulum have no specific signs so difficult to diagnose High index of possibility of the Meckel's diverticulum is essential to manage it properly. The aim of presenting these case reports is to share our experience in these cases and to make clinicians aware of the Meckel's diverticulum.

## Case report

**Case 1:** A five year old boy diagnosed as acute appendicitis. He was taken for emergency operation. Laparotomy revealed inflamed and obstructed Meckel's diverticulum. The obstructed part resected and ileoileal anastomosis was done. Histopathology confirmed the diagnosis.

**Case 2:** A 6 years old boy Presented with chronic pain in abdomen. His ultrasonography showed inflamed Meckel's diverticulum. He underwent elective laparotomy. There was a band extending from the ileum to the umbilicus. At the umbilicus there was cystic swelling. (Fig. 1) There was no communication between the cyst and the umbilicus. Resection and anastomosis with excision of the band and cyst was done. The postoperative course was uneventful. Histopathology confirmed the diagnosis.

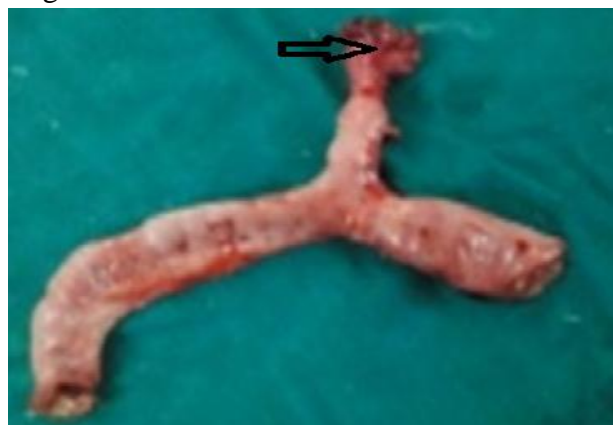**Case 3:** Ten years old boy presented in the emergency with the signs suggestive peritonitis. He underwent emergency laparotomy. There was perforation of Meckel's diverticulum at its base. (Image no2) .Resection and anastomosis was done. The postoperative course was uneventful. Histopathology confirmed the diagnosis. [Fig 2]

**Case 4:** Thirteen-year-old boy was presented with intestinal obstruction. Plain x-ray abdomen-erect and USG abdomen confirmed the diagnosis. Except leucocytosis all other blood report were normal. The laparotomy showed gangrenous small bowel around the constricting band of Meckel's diverticulum. The affected part excised and anastomosis was done. Histopathology confirmed the diagnosis.

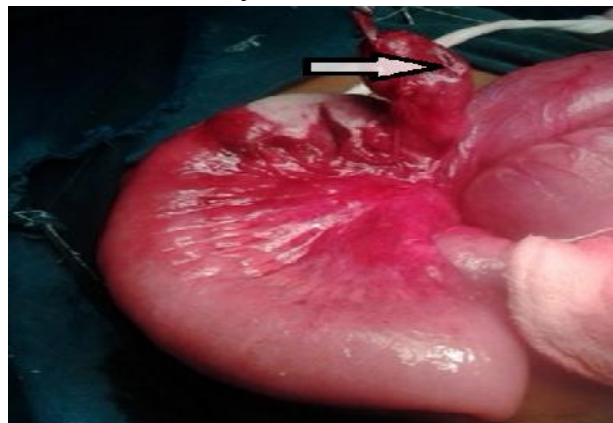**Case 5:** Eighteen year-old boy was presented with signs and symptoms of intestinal obstruction in shock. He was operated for acute appendicitis six months back by the Mac Burneys incision. He had leucocytosis, decreased platelet count, Raised blood urea and creatinine. He was taken for emergency surgery. On exploring the abdomen, we found the small bowel volvulus with extensive gangrene due the band extending from small intestine to the umbilicus. Resection and anastomosis was

performed. Postoperatively the patient went into the renal failure. He received two hemodialysis. He expired, gave the message that every effort must be taken to exclude the Meckel's diverticulum and to treat it properly. Histopathology confirmed the diagnosis.

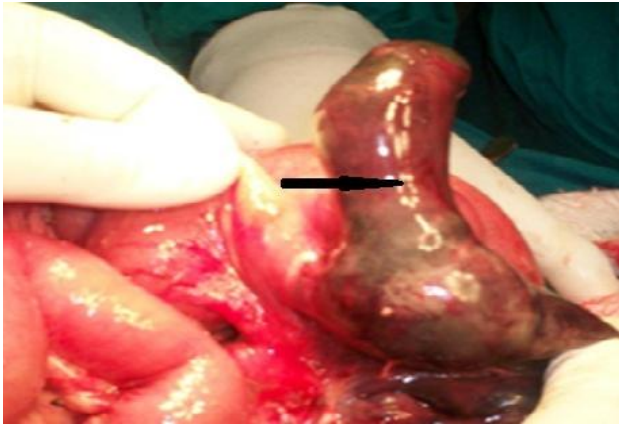
**Case 6-** Seventy five year-old male patient admitted with generalized abdominal pain, vomiting and absolute constipation since two days before admission. He gave the history of operation two years back for blunt abdominal trauma. He was taken for emergency laparotomy for intestinal obstruction. On exploration, a Meckel's diverticulum with a length of seventeen cm was found, with adhesions extending from Meckel's diverticulum to the umbilicus. Meckel's diverticulum showed gangrene. (Fig 3). Adhesiolysis and resection- anastomosis was performed. The post-operative course was unremarkable. Histopathology confirmed the diagnosis.



**Fig.1: Resected small intestine with Meckel's diverticulum and cyst.**



**Fig.2: Arrow shows perforation of Meckel's diverticulum at its base.**



**Fig.3: Arrow shows gangrene of meckel sdiverticulum**

## DISCUSSION

German surgeon Wilhelm Fabricius Hildanus was first described the diverticulum in 1598, the entity was not named until 1809, when Johann Friedrich Meckel reported diverticulum's anatomy and embryology in his research.<sup>2,3</sup> Furthermore, Meckel also showed that the incomplete obliteration of the vitelline duct can result in not only Meckel diverticulum but also enterocysts, mesodiverticular bands and intestinal-umbilical fistulas. Salzer became the first to identify ectopic mucosa within the diverticulum in 1904.<sup>4</sup> Meckel's diverticulum is located on the antimesenteric border of ileum around 45 to 60 cm proximal to ileocecal valve. It is usually 3-5 cm 2% are in length. Its walls are made up of three layers and are similar to the intestinal wall. It derives its arterial blood supply from superior mesenteric artery.<sup>5-7</sup> It is present in 2% of population. 2 feet from the ileocecal valve. 2 inches in length. symptomatic. 2 types of common ectopic tissues are present. 2 times more boys are affected. In the present case report all the patients are male. Furthermore, it can be attached to the umbilical region by the vitelline ligament, with the possibility of vitelline cysts, or even a patent vitelline canal forming a vitelline fistula when the umbilical cord is cut. Torsions of intestine around the intestinal stalk may also occur, leading to obstruction, ischemia, and necrosis. A six years old boy in the case report five presented with cyst at the umbilical side. The male patient in the case reports one, two,

three, four and five were asymptomatic and presented as intestinal obstruction with gangrene. One patient expired in the immediate postoperative period.<sup>7</sup> The majority of people with Meckel's diverticulum are asymptomatic. If symptoms occur, they typically appear before two years of age. Meckel's diverticulitis occasionally may present with all the features of acute appendicitis. The presence of ectopic gastric cells lead to acid-peptic disease. Bleeding, strangulation of bowel, bowel perforation or bowel obstruction are known complications, treatment involves surgical resection of the Meckel's diverticulum itself along with the adjacent bowel segment. In patients without any complications, treatment involves surgical resection of the Meckel's diverticulum only.<sup>8</sup> In every case of appendectomy / laparotomy a search for Meckel's diverticulum must be done and if found Meckel's diverticulectomy or resection should be performed to avoid secondary complications arising from it

## CONCLUSION

Meckel's diverticulum is a rare entity. It may remain asymptomatic. It may present with life threatening complications. Every effort should be taken to exclude Meckel's diverticulum in every case of abdominal pain.

## ACKNOWLEDGEMENT

The authors gratefully acknowledge the support from the management of Pravara Medical Trust, PIMS and Principal Rural Medical College, Loni. We appreciate the help of colleagues in the surgery department. We are grateful to the patients for their cooperation consent.

## REFERENCES

1. Neil J. McC, Mortensen. The small and large intestines. IN Bailey & Love's short practice of surgery. 23<sup>rd</sup> Edition. chapter 57, 1033.

2. Jay GD III, Margulis RR, McGraw AB. Meckel's diverticulum: a survey of 103 cases. *Arch Surg.* 1950;61:158–169
3. Haber JJ. Meckel's diverticulum: review of literature and analytical study of 23 cases with particular emphasis on bowel obstruction. *Am J Surg.* 1947;73:468–85.
4. Mortensen NJ, Jones O. The Small and Large Intestines. In Bailey & Love's Short Practice of Surgery 24th edition. Edited by Russell RCG, Williams NS, Bulstrode CJK Arnold. 2004, 1159-60.
5. Evers BM. Small Intestine. In Sabiston Textbook of Surgery. 17th edition. Edited by Townsend CM. Elsevier; 2004:1366-1368.
6. Whang EE, Ashley SW, Zinner MJ. Small intestine. In Schwartz's Principles of Surgery. Eighth edition. Edited by Brunnicardi FC. McGraw-Hill; 2005:1043-1044.
7. Yamaguchi M, Takeuchi S, Awazu S: Meckel's diverticulum: investigation of 600 patients in Japanese literature. *Am J Surg* 1978, 136:247-49.
8. Horn F, Trnka J, Simickova M, Duchaj B, Makaiova I. Symptomatic Meckel's diverticulum in children. *Rozhl Chir* 2007, 86(9):480-2