

## PRIMARY GASTRIC ACTINOMYCOSIS: A RARE CASE REPORT

Mohit Bhatia<sup>1</sup>, Archana Thakur<sup>2</sup>, Bibhabati Mishra<sup>3</sup>, Vinita Dogra<sup>4</sup>

### ARTICLE INFO

Received: 26<sup>th</sup> July 2015

Revised: 20<sup>th</sup> Aug 2015

Accepted: 20<sup>th</sup> Sep 2015

**Authors details:** <sup>1</sup>Senior Resident, <sup>2,4</sup>Director Professor, <sup>3</sup>Director Professor & Head, Department of Microbiology, Govind Ballabh Pant Institute of Post Graduate Medical Education and Research, New Delhi, India

**Corresponding author:** Mohit Bhatia Department of Microbiology, Govind Ballabh Pant Institute of Post Graduate Medical Education and Research, New Delhi, India.

**Email:** docmb1984@gmail.com

**Keywords:** *Actinomyces spp.*, Primary gastric actinomycosis, Gastric adenocarcinoma

### ABSTRACT

Actinomycosis is a chronic disease characterized by abscess formation, tissue fibrosis, draining sinuses and ulcers caused by the filamentous, gram-positive anaerobic or microaerophilic bacterial species of the genus *Actinomyces*. Actinomycosis mainly presents in three forms namely cervicofacial (31-65%), abdominopelvic (20-36%) and thoracic (15-30%) respectively. Primary gastric actinomycosis is extremely rare, with only 24 cases reported till date. We present a case report of a thirty five years old female patient who was admitted in a super specialty hospital with complaints of low grade intermittent fever, abdominal pain and two discharging sinuses on anterior abdominal wall. Clinical, radiological, microbiological and pathological evaluation revealed findings suggestive of primary gastric actinomycosis with underlying gastric adenocarcinoma in this patient. To the best of our knowledge, this is the first ever report of primary gastric actinomycosis from India.

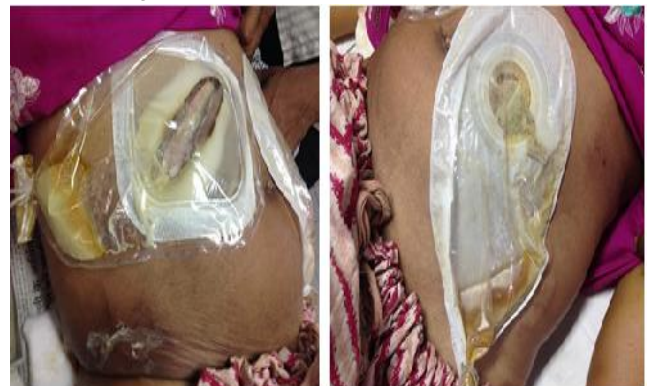### INTRODUCTION

Actinomycosis is a chronic disease characterized by abscess formation, tissue fibrosis, draining sinuses and ulcers. It is caused by the filamentous, gram-positive anaerobic or microaerophilic bacterial species of the genus *Actinomyces*.<sup>[1]</sup> Actinomycosis mainly presents in three forms: cervicofacial (31-65%), abdominopelvic (20-36%) and thoracic (15-30%).<sup>[2,3]</sup> Abdominal actinomycosis has often been called "one of the greatest imitators in clinical practice".<sup>[4]</sup> It often presents as an indolent chronic suppurative process with atypical symptoms that are misdiagnosed as neoplasms and other inflammatory diseases like tuberculosis or Crohn's disease.<sup>[5]</sup> There is a predilection for appendix and ileocecal region of the bowel and thus, it can easily mimic colonic adenocarcinoma, intestinal tuberculosis, chronic appendicitis or regional enteritis.<sup>[6]</sup> When outside the intestine, abdominal actinomycosis generally grows by local spread with rare incidences of haematogenous or lymphatic dissemination.<sup>[7]</sup> Primary gastric actinomycosis is extremely rare, with only 24 cases reported till date.<sup>[8-14]</sup> The rarity of gastric involvement by *Actinomyces spp.* has been attributed to the high luminal acidity of stomach, as a result of which, the organisms are either killed or their growth is inhibited.<sup>[11]</sup> We hereby present a case of primary gastric actinomycosis, which to the best of our knowledge, is the first ever report from India.

### CASE REPORT

A thirty five years old female patient was admitted in a super specialty hospital with complaints of low grade intermittent fever, abdominal pain and discharging sinuses on anterior abdominal wall of one week duration. The

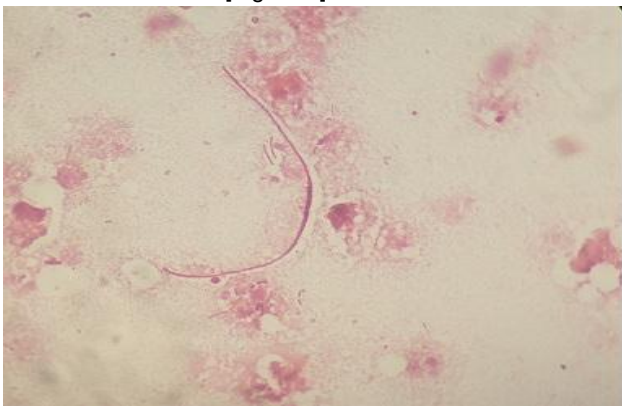
patient revealed that one month prior to the appearance of discharging sinuses, she had abdominal swelling. There was also history suggestive of loss of appetite and significant weight loss. Although, there was no significant past history suggestive of use of Intra Uterine Contraceptive Device (IUCD), however, this patient had undergone cholecystectomy for cholelithiasis at a private nursing home six months ago. On examination, the patient was febrile and had pallor. No icterus, cyanosis, clubbing, lymphadenopathy or edema were observed. Systemic examination revealed no abnormality except for the presence of two sinuses discharging frank pus on anterior abdominal wall. Sinus openings were raised, inflamed and flared up [Figures 1a & 1b].



**Fig 1:(a & b). Discharging sinuses on anterior abdominal wall**

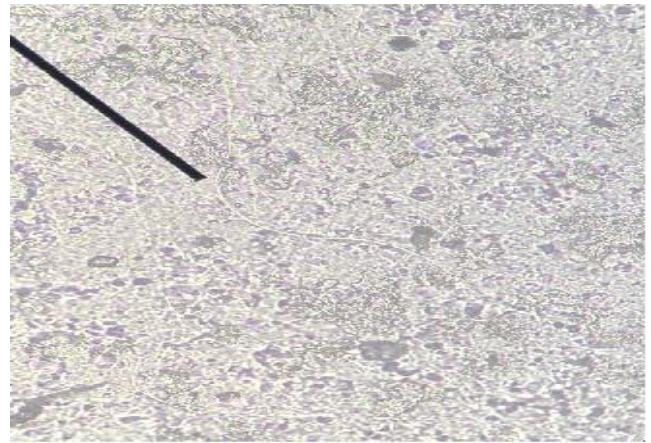
The following investigations were carried out, the results of which are as follows: Complete haemogram revealed anaemia (hemoglobin: 5.5 gram%) and leucocytosis (total leucocyte count: 20,400/cu.mm of blood) respectively.

Ultrasonography of abdomen revealed eccentric asymmetric wall thickening of gastric antro-pyloric region of maximum thickness 3 cm with loss of mural stratification. Few enlarged perigastric lymph nodes of size 12 mmx10 mm each were also seen. Contrast enhanced computerized tomography (CECT) of abdomen revealed thickening of gastric mucosa with formation of a mass extending to anterior abdominal wall and present up to transverse colon. Upper gastro intestinal endoscopy revealed the presence of a large area of elevated surface of size 4 cmx5cm near lesser curvature of stomach. Two openings each of size 1cmx1cm with smooth margins probably containing some necrotic material were visualized in this area. The overlying mucosa of elevated surface appeared to be slightly nodular and abnormal. Gastric biopsy samples collected during this procedure were subjected to histopathological examination which revealed the presence of neoplastic glands (present in lamina) lined by cells showing nuclear pleomorphism, stratification, high Nuclear: Cytoplasmic ratio and moderate amount of eosinophilic cytoplasm suggestive of moderately differentiated gastric adenocarcinoma. Pus and necrotic material collected from sinuses was subjected to Gram stain, Ziehl-Neelson stain and aerobic culture and sensitivity. On macroscopic examination, the pus was yellow to brown in color, thick, fowl smelling with presence of numerous granules which were yellow to white in color and approximately 0.5-1mm in size. Gram stain of pus sample revealed the presence of numerous pus cells, occasional Gram negative bacilli and numerous Gram positive non-fragmented, non-branching, thin filamentous bacteria [Figure 2].

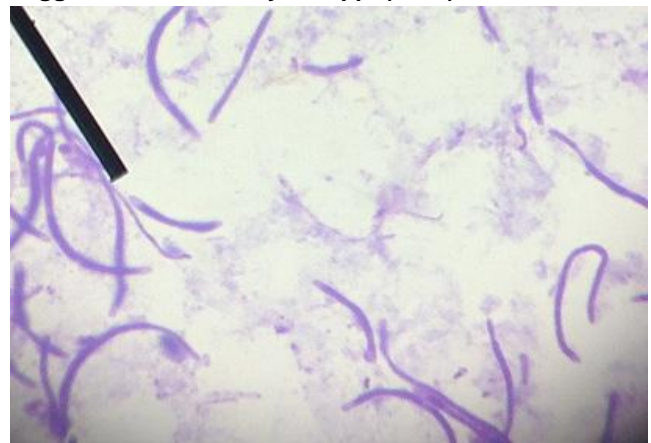


**Fig 2: Gram stain of pus sample showing Gram positive, non-branching, thin filamentous bacteria and Gram negative bacilli (1000X)**

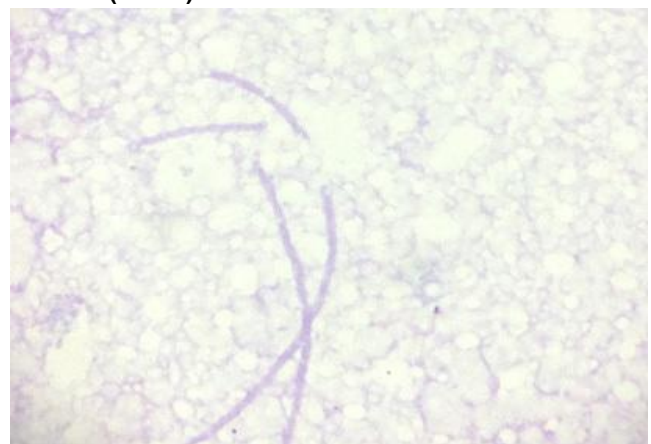
No acid fast bacilli were seen on Ziehl-Neelson stain using 3% acid-alcohol as decolorizer. Taking all sterile precautions, the granules present in pus sample of this patient were transferred to several glass slides and crushed with the help of cover slips and wooden handle of inoculating wire. Potassium hydroxide mount examination of crushed granules revealed the presence of numerous aseptate filamentous structures approximately 0.5 to 1µm in size [Figure 3]. Gram stain and modified Ziehl-Neelson stain (using 1% sulfuric acid as decolorizer) of crushed granules respectively revealed the presence of numerous Gram positive and non-acid fast, non-fragmented, non-branching, thin filamentous bacteria without any chains of spores suggestive of *Actinomyces spp* [Figures 4 & 5].



**Fig 3: KOH mount of crushed granules showing aseptate, non-branching, thin filamentous structures suggestive of Actinomyces spp. (400X)**



**Fig 4: Gram stain of crushed sulfur granules revealing Gram positive non-branching, thin filamentous bacteria (1000X)**



**Fig 5: Modified Ziehl-Neelson stain showing non acid fast structures morphologically resembling Actinomyces spp. (1000X)**

*Escherichia coli* sensitive to amikacin, imipenem, meropenem and ertapenem was isolated after twenty four hours of aerobic incubation of pus sample. In lieu of the clinical picture, aforementioned macroscopic and microscopic findings, special requisition was sent from the laboratory to the clinicians for sending some more pus and necrotic debris, collected from sinuses of this patient, for performing anaerobic culture for confirmation of actinomycosis. However, by the time this requisition was received by the clinicians, the patient had deteriorated

clinically and finally expired due to cardiac arrest owing to which a second sample could not be collected.

Suggestive history, predisposing factors in the form of surgery and presence of gastric adenocarcinoma, endoscopic findings and presence of discharging sinuses, macroscopic and microscopic microbiological findings suggest that it was a case of primary gastric actinomycosis.

## DISCUSSION

*Actinomyces spp.* are often found as saprophytes in the oral cavity, gastrointestinal and female genital tract. The destruction of the muscular barrier by trauma in the form of surgeries, endoscopic manipulation, immune suppression as in leukemia, lymphoma and other malignancies, renal insufficiency, renal transplant, diabetes and chronic inflammatory diseases are recognized as predisposing factors for penetration by these organisms.<sup>[15]</sup> Upon penetration, these organisms in turn result in characteristic clinical manifestations in different parts of the body at varying frequencies. Primary gastric actinomycosis frequently presents as low-grade fever, epigastric pain, weight loss, upper GI bleeding and rarely symptoms of gastric outlet obstruction.<sup>[3,12,14]</sup> The patient under study presented with similar clinical features suggestive of actinomycosis. She had undergone cholecystectomy six months ago and was diagnosed on histopathological examination as a case of gastric adenocarcinoma later on, both of which are predisposing factors for acquiring abdominal actinomycosis.

There are no specific radiological or endoscopic findings suggestive of this condition. CT findings mostly demonstrate an infiltrative lesion with diffuse gastric wall thickening suggestive of gastric adenocarcinoma or lymphoma.<sup>[2,14]</sup> Endoscopic findings of the disease may simulate a gastric neoplasm and include submucosal tumor-like or infiltrative lesions and occasionally, mucosal ulceration. In the present case, endoscopic findings revealed elevated surface and two openings containing necrotic material near the lesser curvature of stomach. Because of the submucosal localization of the inflammatory process, endoscopic biopsy specimens usually reveal nonspecific inflammatory changes.<sup>[14]</sup> Out of the twenty four reported cases of primary gastric actinomycosis, only three cases have been diagnosed pre-operatively by histopathological examination of endoscopic biopsy specimens.<sup>[9,10,14]</sup> In a case reported by Khaleel Al-Obaidy et al, the patient was subjected to upper gastrointestinal endoscopy twice, carried out one week apart. Actinomycosis was detected by histopathological examination only in the second biopsy which was obtained from an area containing brownish fibrinopurulent inflammatory exudate.<sup>[14]</sup> In the present case also it is possible that biopsy samples may not have been obtained from the necrotic area and therefore, the diagnosis of actinomycosis was missed. However, histopathological examination revealed gastric adenocarcinoma as the most probable underlying cause of acquiring this infection in contrast to most reported cases of gastric actinomycosis,

in which it was impossible to trace the mechanism by which *Actinomyces spp.* had reached the gastric wall.<sup>[14]</sup>

Actinomycosis is often but not always characterized by the presence of sulfur granules which occur in 50% of the cases. Although the presence of sulfur granules strongly suggests a diagnosis, these are not pathognomonic for the disease.<sup>[16,17]</sup> The differential diagnosis of sulphur granules includes nocardiosis, streptomyces, chromomycosis, eumycetoma and botryomycosis.<sup>[18]</sup> In the case under study, preliminary microbiological examination of pus and necrotic material obtained from discharging sinuses revealed the presence of organisms morphologically resembling *Actinomyces spp.* and largely ruled out the aforementioned conditions.

Culture is negative in >76% cases of gastric actinomycosis.<sup>[14]</sup> In our case, aerobic culture of pus and necrotic material obtained from discharging sinuses yielded *Escherichia coli*. Generally typical actinomycotic lesions contain one to ten bacterial species in addition to the pathogenic actinomycetes. These bacteria are responsible for early symptoms of the disease and treatment failures in addition to acting as probable synergistic pathogens that strengthen the comparatively low invasive power of *Actinomyces spp.*<sup>[19]</sup> Whether *Escherichia coli*, which is known to cause botryomycosis<sup>[20]</sup>, had contributed to the development of mycetoma in our case remains unclear. Unfortunately, anaerobic culture for isolation and speciation of *Actinomyces spp.* could not be attempted due to early death of the patient.

## CONCLUSION

Primary gastric actinomycosis is an extremely rare disease and often missed by routine diagnostic tests if the sample is not specifically collected from the affected area. A high level of suspicion is required both by gastroenterologists and pathologists in order to correctly diagnose this condition. Actinomycosis should be considered in the differential diagnosis of radiological and upper gastrointestinal endoscopic findings of gastric wall thickening, particularly in patients with history of abdominal surgery, trauma or immune compromised status. In order to avoid the possibility of missing the diagnosis, the pathologists should be more vigilant and employ appropriate staining techniques when gastric endoscopic biopsy samples reveal the presence of subtle changes such as inflammatory exudates.

## ACKNOWLEDGEMENTS

Department of Gastroenterology, Govind Ballabh Pant Institute of Post Graduate Medical Education and Research, New Delhi

**Conflict of Interest:** Nil

## REFERENCES

1. Ferrari TC, Couto CA, Murta-Oliveira C, Conceicao SA, Silva RG. Actinomycosis of the colon: A rare presentation. Scand J Gastroenterol, 2000;35:108-9

2. Isik B, Aydin E, Sogutlu G, Ara C, Yilmaz S, Kirimlioglu V. Abdominal actinomycosis simulating malignancy of the right colon. *Dig Dis Sci.* 2005;50:1312–14
3. Choi MM, Beak JH, Lee JN, Park S, Lee WS. Clinical features of abdominopelvic actinomycosis: report of twenty cases and literature review. *Yonsei Med J.* 2009;50:555–59
4. Dayan K, Neufeld D, Zissin R, Bernheim J, Paran H, Schwartz I et al. Actinomycosis of the large bowel: Unusual presentations and their surgical treatment. *Eur J Surg*,1996;162:657-60
5. P. Acquaro, F. Tagliabue, G. Confalonieri, P. Faccioli, and M. Costa. Abdominal wall actinomycosis simulating a malignant neoplasm: case report and review of the literature. *The World Journal of Gastrointestinal Surgery*, 2010;2(7):247–50
6. Richards RJ, Grayer D. Actinomycosis: A rare cause of vesicocolic fistula. *Am J Gastroenterol*, 1989;84: 677-9
7. Meyer P, Nwariaku O, McClelland RN, Gibbons D, Leach F, Sagalowsky AI, et al. Rare presentation of actinomycosis as an abdominal mass: report of a case. *Dis Colon Rectum*, 2000;43:872-5
8. Oksüz M, Sandikçi S, Culhaci A, Egesel T, Tuncer I. Primary gastric actinomycosis: a case report. *Turk J Gastroenterol*, 2007;18:44–46
9. Lee SH, Kim HJ, Kim HJ, Chung IK, Kim HS, Park SH, et al. Primary gastric actinomycosis diagnosed by endoscopic biopsy: case report. *Gastrointest Endosc.*, 2004;59:586–89
10. Minamino H, Machida H, Tominaga K, Kameda N, Okazaki H, Tanigawa T, et al. A case report on primary gastric actinomycosis. *Gastroenterol Endosc.*, 2011;53(2):262–69
11. Skoutelis A, Panagopoulos C, Kalfarentzos F, Bassaris H. Intramural gastric actinomycosis. *South Med J.*,1995;88:647–50
12. Lee CM, Ng SH, Wan YL, Tsai CH. Gastric actinomycosis. *J Formos Med Assoc.*, 1996;95:66–68
13. Mazuji MK, Henry JS. Gastric actinomycosis: case report. *Arch Surg.*, 1967;94:292–93
14. Khaleel Al-Obaidy, Fatimah Alruwaili, Areej Al Nemer, Raed Alsulaiman, Zainab Alruwaili, Mohamed A Shawarby. Primary gastric actinomycosis: report of a case diagnosed in a gastroscopic biopsy. *BMC Clin Pathol.*, 2015; 15: 2
15. D. C. Dominguez, S. J. Antony. Actinomyces and nocardia infections in immunocompromised and non immunocompromised patients. *Journal of the National Medical Association*, 1999; 91(1): 35–39
16. Yeguez J.F., Martinez S., Sands L.R., Hellinger M.D. Pelvic actinomycosis as malignant large bowel obstruction: A case report and a review of the literature. *Am Surg*, 2000;66(1):85-90
17. Cintron J.R., Del Pino A., Duarte B., Wood D. Abdominal actinomycosis. *Dis Colon Rectum*,1996;39(1):105-8
18. Omsby AH, Bauer TW, Hall GS. Actinomycosis of the cholecystic duct: case report and Review Pathology, 1998;30:65-7
19. Schaal KP, Lee HJ. Actinomycete infections in humans -- a review. *Gene*, 1992;115:201-11
20. B Devi, B Behera, ML Dash, MR Puhan, SS Pattnaik, S Patro. Botryomycosis. *Indian J Dermatol.*, 2013 Sep-Oct; 58(5): 406