



# International Journal of Medical Research & Health Sciences

[www.ijmrhs.com](http://www.ijmrhs.com)

Volume 3 Issue 3

Coden: IJMRHS

Copyright ©2014

ISSN: 2319-5886

Received: 23<sup>rd</sup> Apr 2014

Revised: 28<sup>th</sup> May 2014

Accepted: 5<sup>th</sup> Jun 2014

## Case report

### **PYOGENIC GRANULOMA: POST OPERATIVE COMPLICATION OF PTERYGIUM SURGERY**

\*Nigwekar Shubhangi P<sup>1</sup>, Chaudhari Sagar V<sup>2</sup>, GupteChaitanya P<sup>2</sup>, BankarMahima S<sup>2</sup>

<sup>1</sup>Professor, <sup>2</sup>Post Graduate Student, Department of Ophthalmology, Rural Medical College, Loni, Maharashtra, India

\*Corresponding author email: shubhangi2501@yahoo.in

## **ABSTRACT**

The most common complication of pterygium surgery is postoperative recurrence. These recurrences are reduced with conjunctival autograft technique. However, with this graft surgery, post surgical wound-healing response may be more intense and may lead to Tenon's granuloma or pyogenic granuloma or stitch granuloma. These granulomas are treated either with frequent topical instillation of steroid eye drops or surgical excision. A 27 years old lady presented with painless, progressive nodular mass after her left eye pterygium excision with conjunctival autograft surgery on her follow up of 15<sup>th</sup> post operative day. The clinical diagnosis was post-operative granuloma and patient underwent excisional biopsy. Histopathology confirmed the diagnosis of pyogenic granuloma. The patient was treated with postoperative tapering topical steroid drops and there was no recurrence even after 1 year.

**Keywords:** Pyogenic granuloma, Pterygium excision with conjunctival autograft.

## **INTRODUCTION**

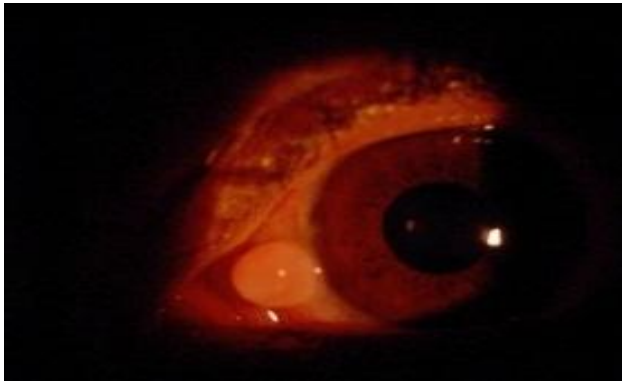
Pterygium is a common degenerative condition of the subconjunctival tissue. It affects temporal or nasal perilimbal area, encroaches over cornea and leads cosmetic and visual disturbances.<sup>1</sup> Surgical excision is the treatment of choice. The most common complication of pterygium surgery is postoperative recurrence. These recurrences are reduced with conjunctival autograft.<sup>2</sup> However with this graft surgery, post surgical wound-healing response may be more intense and may lead to Tenon's granuloma or pyogenic granuloma or stitch granuloma. These granulomas are treated either with frequent topical instillation of steroid eye drops or surgical excision. Here we are describing the surgical management of the post pterygium surgery -pyogenic granuloma.

## **CASE REPORT**

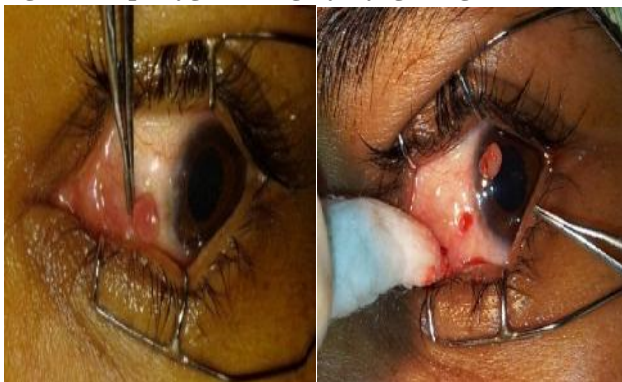A 27 years old lady came to Pravara Rural Hospital, Loni for first follow up after her left eye progressive pterygium excision with conjunctival autograft surgery. She presented with nasal limbal mass in the operated eye, which was painless and gradually increasing in size without any visual problems.

On local examination, left eye showed a vascularized, pedunculated, nontender and well-defined pinkish mass measuring approximately 5 × 5 mm close to the nasal limbus on the graft bed (Fig- 1). Ophthalmological examination of both eyes showed normal anterior and posterior segments except this mass. General and systemic examination of the patient was noncontributory. Patient was sero negative for HIV. Clinical diagnosis was postoperative granuloma and patient underwent excisional biopsy of the lesion under local anesthesia

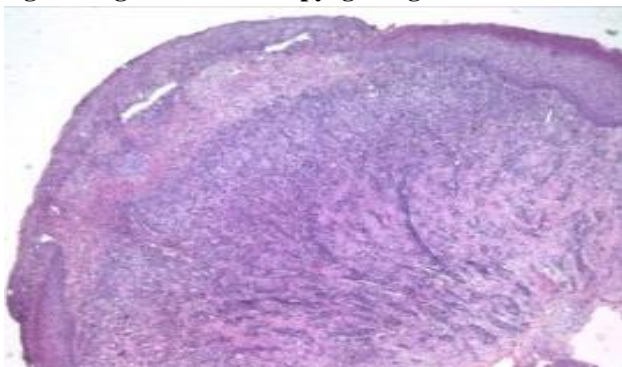
(Fig- 2). The mass was sent for histopathology which revealed granulation tissue lined by squamous cells suggestive of a pyogenic granuloma (Fig- 3). Patient was advised for instillation of topical steroids for a month in tapering dose. One year follow up showed no recurrence (Fig- 4).



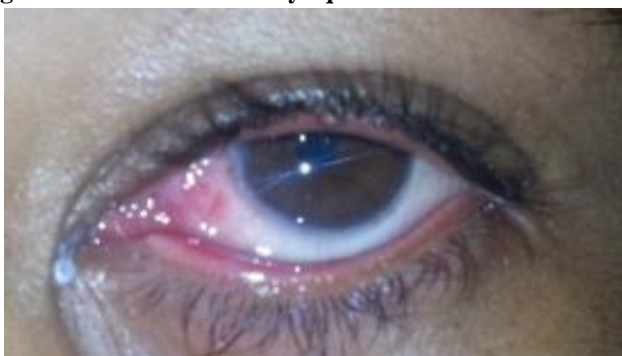**Fig 1: Post pterygium surgery-Pyogenic granuloma**



**Fig 2: Surgical excision of pyogenic granuloma**



**Fig 3: Histopathology of pyogenic granuloma showing granulation tissue lined by squamous cells**



**Fig 4: Postoperative**

## DISCUSSION

Pterygium is a degenerative condition of the subconjunctival tissue. It proliferates as vascularized granulation tissue, invade the cornea, destroy the superficial layer of the stroma and Bowman's membrane and it is covered by conjunctival epithelium. These patients present with complaints of redness, lacrimation, foreign body sensation, growing mass in the eye and a rarely visual disturbance in the form of blurring and diplopia.<sup>3</sup>

There are two types of pterygium. Progressive pterygium and atrophic pterygium. Progressive pterygium presents as thick, fleshy, reddish mass with prominent blood vessels and atrophic pterygium presents as thin, pale, flat whitish mass devoid of fresh blood vessels and leads to ocular surface disorder.<sup>4</sup>

If the pterygium is small atrophic and without any symptoms, it is best left alone with lubricant drops and periodic follow up. In case of progressive pterygium surgeries like pterygium excision with bare sclera, excision with conjunctival autograft, excision with Mitomycin-C (MMC) application and excision with Amniotic Membrane Transplant (AMT) are considered as treatment modalities.<sup>5</sup>

Pterygium excision with only bare sclera leads to recurrence up to 80-90 %. Conjunctival autograft or AMT or MMC application prevent these recurrences.<sup>6</sup> However post operative complications like pyogenic granuloma can occur with these surgeries due to excess intra-operative tissue handling.

Hirst LW showed the incidence of pyogenic granuloma up to 40%, 7.9%, and 9.2% when bare scleral excision is accompanied by an intraoperative application of MMC, conjunctival autograft, and AMT, respectively.<sup>7</sup>

The formation of granuloma occurs within 1 week after pterygium surgery as a proliferative, inflammatory lesion. Localized suture irritation and excessive tissue handling intra-operatively are some of the causes for the granuloma formation.<sup>8,9</sup>

Small granulomas may spontaneously resolve with the frequent application of topical steroids, but larger granulomas require the simple surgical excision.

Histologically, they have a lining of stratified squamous epithelium which is ulcerated at one focus. The subepithelial area shows granulation tissue

composed of proliferating small capillaries fibroblast and infiltration by chronic inflammatory cells mainly lymphocytes.<sup>10</sup>

In our present case the patient was young; pterygium was in progressive stage, which was a high risk factor for postoperative recurrence. To reduce the recurrence, we performed the pterygium excision with conjunctival autograft using absorbable 8-0 vicryl suture. Intraoperative excess handling of tissue and conjunctival autograft suture irritation might have lead to pyogenic granuloma after the conjunctival autograft surgery.

Complete surgical excision of the pyogenic granuloma and post-operative frequent topical steroids gave good results and there was no postoperative recurrence for 1 year.

## CONCLUSION

Pyogenic granuloma may present after pterygium excision with conjunctival autograft technique. Surgical excision of large pyogenic granuloma with post-operative topical steroids gives good result without recurrence.

## ACKNOWLEDGEMENT

We thank Professor and HOD Dr. Dongre and Professor Dr. Karle from Department of pathology, RMC, Loni for providing the histopathological report.

**Conflict of interest: Nil**

## REFERENCES

1. Janey L. Wiggs, David Miller, Yanoff & Duker Ophthalmology; Cornea and ocular surface disorders, Mosby Elsevier;2009:3<sup>rd</sup>ed:248-49
2. John E Sutphin , JR, AAO. External disease and cornea section 8,LEO;2007-2008;429-32
3. Ramanjit Shhota, Radhika Tandon. Parson's diseases of the eye; disease of conjunctiva, Elsevier; 2007:20<sup>th</sup> edition: 175-177.
4. Jack J Kanski, Brad Bowling.clinical ophthalmology a systemic approach; conjunctiva, Elsevier;2011:7<sup>th</sup> edition;163-66
5. Frau E, Labetoulle M, Lautier-Frau M, Hutchinson S, Offret H. Corneo-conjunctival autograft transplantation for pterygium surgery. Acta Ophthalmol Scand. 2004; 82:59-63
6. Levy RL, Naidu S, Jacobson L. Safety and efficacy of the technique of complete Tenon's membrane excision and mitomycin C in pterygium surgery. Eye Contact Lens.2005;31:105-08
7. Hirst LW. The treatment of pterygium. Surv Ophthalmol. 2003;48:145-80
8. Fryer RH, Reinke KR. Pyogenic granuloma: a complication of transconjunctival incisions. Plast Reconstr Surg. 2000;105:1565-66
9. Bekibele CO, Baiyeraju AM, Olusanya BA. Pterygium treatment using 5-FUas adjuvant treatment compared to conjunctiva autograft. Eye (Lond).2008;22(1):31-34
10. Varssano D, Michaeli-Cohen A, Loewenstein A. Excision of pterygium and conjunctivalautograft. Isr Med Assoc J. 2002; 4:1097-100