



# International Journal of Medical Research & Health Sciences

[www.ijmrhs.com](http://www.ijmrhs.com)

Volume 3 Issue 4

Coden: IJMRHS

Copyright ©2014

ISSN: 2319-5886

Received: 2<sup>nd</sup> July 2014

Revised: 5<sup>th</sup> Aug 2014

Accepted: 12<sup>th</sup> Sep 2014

## Case report

### SPONTANEOUS BILATERAL RUPTURED AND UNRUPTURED TUBAL ECTOPIC PREGNANCIES: A CASE REPORT AND LITERATURE REVIEW FROM NIGER DELTA NIGERIA

\*Ekine A A<sup>1</sup>, Udoye EP<sup>2</sup>

<sup>1</sup>Department of Obstetrics and Gynaecology, Niger Delta University Teaching Hospital, Okolobiri, Bayelsa State, Nigeria.

<sup>2</sup>Department of Anatomical Pathology, Niger Delta University Teaching Hospital, Okolobiri, Bayelsa State, Nigeria.

\*Corresponding author email: adokin1960@gmail.com

## ABSTRACT

Historically ectopic pregnancy and its complications account for the most leading cause of first trimester maternal deaths in the world. Bilateral tubal pregnancies in the absence of a preceding induction of ovulation (or tubal manipulation for assisted conception) are very rare occurrences and are associated with high potentials for causing maternal mortality. We herein report an uncommon mode of presentation of an ectopic pregnancy in a multi-parous woman, with a spontaneous bilateral tubal pregnancy. The Patient presented in shock, which was caused by a ruptured right ampullary tubal ectopic pregnancy with massive haemoperitoneum. During a life saving emergency exploratory laparotomy which showed a ruptured right ectopic pregnancy, an enlarged unruptured left ampullary mass highly suspicious of ectopic pregnancy was also removed. Both tubal pathologies were confirmed as ectopic gestations histopathologically. This case underscores the variety of such occurrences, a high index of suspicion, judicious intra-operative inspection of the contra lateral tube and histopathological evaluation of the specimens.

**Keywords:** Bilateral, Tubal, Ectopic, Pregnancy, Complications

## INTRODUCTION

Ectopic pregnancy has been found to be on the increase in the past three decades and this pattern has not reversed currently, even in our centre. While first trimester maternal mortality as a direct or indirect result of ectopic pregnancy had been on the decline, the incidence and prevalence of ectopic pregnancy is on the rise<sup>1</sup>. Bilateral ectopic pregnancy is a very unique form of twin pregnancy, more commonly seen in assisted reproductive technique, than occurring spontaneously<sup>2,3</sup>. According to medical literatures, approximately 250 cases have been reported, though the actual incidence is unknown and cannot be

determined currently<sup>2</sup>. However a gross estimation of between 1 in 750 and 1 in 1,580 ectopic pregnancies and also 1 in every 200,000 live births is mentioned in most medical literatures<sup>1,4-7</sup>. Other reports have shown spontaneous bilateral pregnancy to be higher in native Africans, possibly due to the higher prevalence of twin pregnancy and pelvic inflammatory diseases, resulting in incidence rate of about 1 in 51 ectopic pregnancies<sup>6,7</sup>. Twin pregnancies can occur in many ways; like bilateral tubal pregnancy of the same gestational age or different ages with both aborting or one aborting

while the other is developing. The involvement of the tube could be unilateral twin ectopic but neighboring structures like the broad ligament, ovary or abdominal structures can be involved<sup>6</sup>. The bilateral tubal twin pregnancy is the rarest form of extra uterine pregnancy<sup>1</sup>. Twin pregnancies in the same tube and heterotopic pregnancies are notably more common after assisted reproductive technique (ART), tubal surgeries, hormonal manipulations for multiple ovulations.<sup>8-11</sup>. Some of the risk factors associated with the ectopic pregnancy include, pelvic inflammatory diseases, intrauterine contraceptives device usage, tubal surgeries, and assisted reproductive techniques<sup>1,3,4,7,11,12</sup>. Diagnosis of bilateral tubal ectopic pregnancies is not easy as they are not always suspected, even ultrasound has its limitations and that is the **reason** why bilateral ectopic pregnancy is mostly encountered unsuspected at laparotomy. Though in many cases conservation of fertility is an important issue, bilateral salpingectomy is often required in some given circumstances. However, efforts should always be made to see the integrity of contra lateral adnexa if attainable. We herein report the first documented case of spontaneous simultaneous bilateral tubal pregnancy in the Niger Delta region occurring in a multipara which was managed by bilateral salpingectomy.

## CASE REPORT

A housewife with primary level of education aged 37 years, gravida 5, para 4 + 0, four alive (three boys and one girl), presented at the Accident and Emergency Department with a four-day history of abdominal pain, a day history of vaginal bleeding, and an episode of fainting attack. Her last menstrual period was on 29-11-2013. She was apparently well for a period of approximately 12 weeks of amenorrhea, after which she experienced lower abdominal pains, which were insidious in onset, initially pronounced in the right supraumbilical region of the abdomen, and later became generalized, colicky in nature with no known aggravating or relieving factors. The pain had persisted for 3 days and so on the fourth day she went for an "abdominal massage" by a native therapist, a common practice in this part of our country, Nigeria. On completion of the native therapy, the woman started having vaginal bleeding. During this long period of amenorrhea, she never sought medical attention nor did a pregnancy test. Initially the

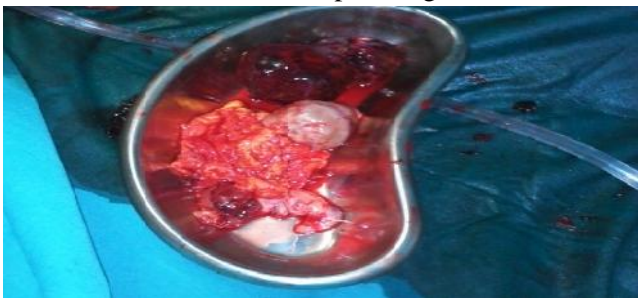vaginal bleeding was scanty, but later it became heavier, necessitating the use of four fully soaked pads with clots. There was no passage of fleshy materials or grape like vesicles, but she afterwards complained of headache, dizziness, and later slumped.

She was sexually active, but never used any form of contraceptives. There was no past history of termination of pregnancy, sexually transmitted disease or use of fertility enhancing drugs. Also, there was no family history of twinning or history of tubal surgeries. The patient has four children, three boys and a girl.

At presentation, she was in respiratory distress and in shock. Her vital signs were Pulse 110beats/minute, Blood pressure 70/40 mmHg, respiratory rate of 38 circles per minute. She was extremely pale, but not jaundiced. Her chest was clinically clear. Abdomen was distended with generalized tenderness and did not move with respiration. Abdominal paracentesis done yielded non-clotting blood. On gentle speculum vaginal examination, the vulva was bloodstained, the cervix looked healthy and there was no significant bleeding through the cervical OS but the posterior fornix was bulging. Bimanual examination was excluded due to the overwhelming evidence of massive haemoperitoneum. Urgent urinary pregnancy test was positive. Pelvic ultrasound scan was not done because of lack personnel at the time, but with the presence of blood in the peritoneum a suspicion of ruptured ectopic pregnancy was strong. The urgent packed cell volume (PCV) done was 14% and initial diagnosis of ruptured ectopic pregnancy in hemorrhagic shock was made. The patient's relatives were counseled on immediate surgical intervention to avoid any consequence adverse outcome since she was not capable of taking any proper decision at that moment. Though she was not quite stable and fit for surgery, a decision for surgical intervention had to be made to avoid imminent fatal incidence.

Immediate resuscitation with intravenous fluids, plasma expanders and blood transfusion was commenced and continued in the emergency explorative laparotomy that was done for her via a midline sub-umbilical incision. Intra-operative findings revealed haemoperitoneum of more than two liters with severe intra-abdominal pelvic adhesions. Right ampullary ruptured ectopic pregnancy was confirmed and salpingectomy was done. Close

inspection of the other organs revealed a distended and unruptured left tube ampullary region measuring about 9 cm by 6 cm. Subsequently, salpingectomy was also done for the left tube, followed by adhesiolysis. The haemoperitoneum was evacuated and warm saline peritoneal lavage was done before closing up. She was transfused with 3 units of blood intraoperatively. Combined broad spectrum antibiotics was commenced immediate postoperative due to the massive adhesions seen during the surgery, though from the patient's history there was no information about previous pelvic inflammatory diseases (PID). The immediate postoperative period was uneventful. The pack cell volume done on the second day post operation was 19% so she had a further transfusion of two units of blood. She was commenced on graded oral sips second day post operation. Sutures were removed on day seven post operation and wound healing was good. A repeat pack cell volume done was 28% and she was discharged home on heamatronics. Before discharge the patient was counseled on the likelihood of future reproductive impairment and the role of IVF and adoption as possible options, if the patient desires more children. The specimen of both fallopian tubes, a haemorrhagic mass from right fallopian tube and omentum were sent for histopathological evaluation.



**Fig1: Kidney dish containing enlarged right and left fallopian tubes with a large haemorrhagic mass from the ruptured right tube and omental tissue from adhesiolysis.**



**Fig 2: Enlarged right ruptured fallopian tube with a haemorrhagic mass attached to it.**



**Fig 3: Cut surface of ruptured right Fallopian tube showing intratubal haemorrhage.**



**Fig 4: Cut surface of haemorrhagic mass attached to the ruptured right fallopian tube showing blood clots with islands of solid tissue.**

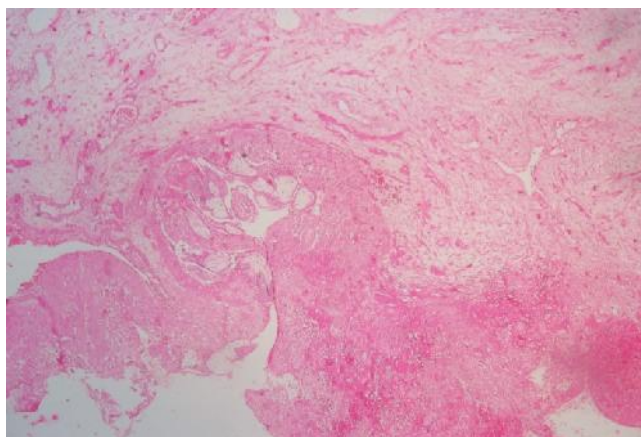


**Fig 5: Dilated left unruptured tube with omental tissue.**

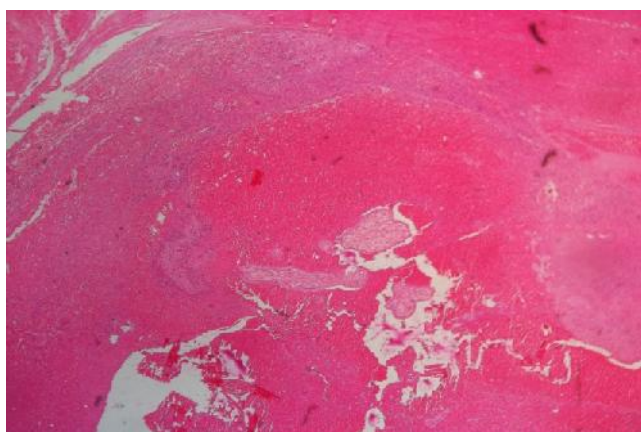


**Fig 6: Cut surface of left fallopian tube showing intratubal haemorrhage.**

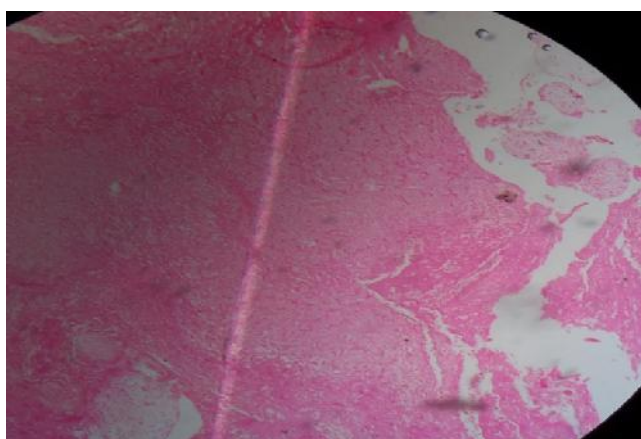
The histopathological report confirmed bilateral tubal ectopic gestations based on the presences of chorionic villi and decidua in both tubes.



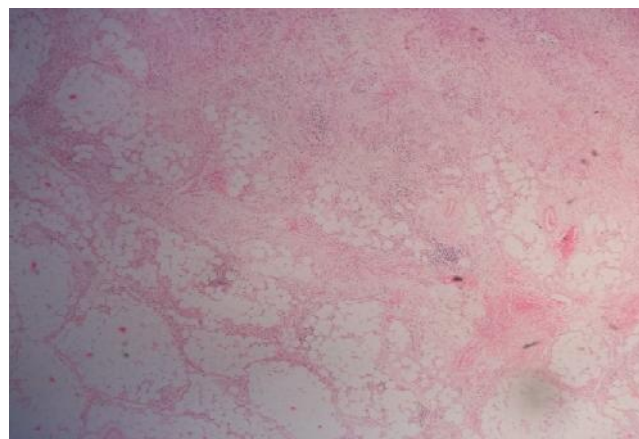
**Fig 7: Histologic section from right fallopian tube showing dilated lumen containing haemorrhage, decidua and chorionic villi. H&E x 100**



**Fig 8: Histologic section of the haemorrhagic mass from the right ruptured fallopian tube showing haemorrhagic necrosis with degenerating chorionic villi and decidua. H&E x 100**



**Fig 9: Histologic section from the left fallopian tube showing dilated lumen containing blood clot within which are chorionic villi. H&E x 100**



**Fig 10: Histologic section from the omental tissue showing focal haemorrhage and dense infiltration of adipose tissue by lymphocytes. H&E x 100**

At follow up four weeks later her clinical state was fine, and PCV was 31%. As at the last follow up visit three months after discharge, she has been well with no complains. The patient gave permission to report the case with pictures, anonymously.

## DISCUSSION

The incidence of bilateral ectopic pregnancy is now known to vary between 1 in 725 to 1 in 1580 of all ectopic pregnancies and estimated to occur in about 1 in 200,000 pregnancies.<sup>4</sup> Bilateral tubal pregnancy in the absence of ovulation induction or ART represents the rarest type of ectopic pregnancies and twin pregnancy in the same tube is of higher frequency than bilateral tubal type.<sup>2</sup> The index case was a simultaneous bilateral ectopic pregnancies, hence represents an exceedingly rare form of ectopic gestation. Only a few cases of simultaneous bilateral pregnancy have been published, about 250 cases, of which many occurred following assisted reproductive treatment.<sup>2</sup> Our case was not only a very rare form, but was spontaneous. Norris' criteria of 1953<sup>8</sup> for a diagnosis of simultaneous bilateral tubal pregnancy required that the chorionic villi in each tube should be sufficient for diagnosis, which is a modification of 1939 criteria by Fishback<sup>13</sup>, which suggested the presence of fetuses or any portion of the fetuses along with placenta material for such diagnosis. Our case satisfied Norris' criteria as indicated by the histopathological report and hence, was confirmed bilateral tubal ectopic pregnancies.

A high index of suspicion and careful examination of the contra lateral tube are necessary for diagnosis of bilateral ectopic pregnancy intra-operatively<sup>11,14,15</sup>.

This is more so as the preoperative diagnosis with ultrasound scan is unreliable<sup>16,17</sup>, with only very few reported cases diagnosed by preoperative ultrasound scanning<sup>2</sup>. Our patient was diagnosed intra-operatively in line with the fact that preoperative diagnosis is uncommon.

The index case was spontaneous as she was not known to be on fertility enhancing medication or to be undergoing assisted reproduction therapies which are known risk factors for bilateral ectopic pregnancy<sup>18</sup>. Also, she had no family history of twin pregnancy, nor was she of the ethnic groups that are prone to twinning in Nigeria<sup>19,20</sup>, as such are further risk factors for bilateral ectopic pregnancy. However, she had extensive pelvic adhesions which were most probably as a result of chronic pelvic inflammatory disease, a notable risk factor for ectopic pregnancy.<sup>1,4</sup> Whether bilateral ectopic pregnancy occurred spontaneously or occurred on a background of ovulation induction or is induced by assisted reproductive techniques, the hallmarks of good management including detailed ultrasound scanning (especially when presentation is not acute or life threatening), judicious intra-operative inspection of the contra lateral tubes, histopathological examination of the specimens and appropriate patient counseling, among others will ensure best practices. Our case presented in shock for which positive peritoneal tap of non-clotting blood and a history of amenorrhea of 12 weeks was sufficient to commence a life-saving intervention. However, other factors were duly observed.

Researchers from eastern Nigeria have stated a preference to salpingostomy when the tubes are intact as that gives the patient hope of future fertility and helps to prevent family disintegration associated with childlessness.<sup>21,22</sup> It has also been observed that for unknown reasons many women fail to become pregnant even after successful reconstructive tubal surgery.<sup>22,23</sup> Documented evidence also showed that recurrent ectopic pregnancies occur in 6-16% of women with a previous history of ectopic<sup>18</sup> Therefore salpingostomy option in the management of ectopic pregnancy should be left for cases that strictly merit it after weighing all the risk against the hope of future fertility for the childless. This implies a sound clinical judgment considering the parity of the patient, marital status, reproductive aspirations, condition at presentation, findings on physical examination, the

experience of the surgical team and the available resources.<sup>24</sup> Our case was a para 4, four alive with good sex ratio, who presented in shock from suspected ruptured ectopic post traditional abdominal massage and was diagnosed of bilateral tubal ectopic pregnancy intra operatively during a life-saving surgical intervention, in which salpingectomy was done for the unruptured tube based on sound clinical judgment.

The principles of treatment of unilateral ectopic gestations can be applied in simultaneous bilateral ectopic pregnancy, since no separate guideline for treatment has been developed due to the rarity of such cases.<sup>25</sup> Apart from laparoscopy being the choice treatment of elective management of ectopic pregnancy, it can be used to examine the contra lateral tube and to diagnose and manage bilateral ectopic pregnancy as in the case of Sommer et al<sup>1,26</sup> Takeuchi et al reported the first case of laparoscopic treatment of bilateral tubal pregnancy in 1995<sup>27</sup>. Currently, reports of primary medical treatment of bilateral tubal ectopic pregnancy with methotrexate are lacking, though since the diagnosis of this condition is usually intra-operative, it may be possible that there would have been such cases in which clinicians were unaware that their medical treatment for unilateral unruptured tubal ectopic pregnancy had resulted in successful management of exiting unruptured pregnancy in the contra lateral tubes.<sup>1</sup>

## CONCLUSION

High index of suspicion and meticulous examination of both tubes and adnexa even in the presence of significant pelvic adhesions coupled with a holistic approach in clinical judgment for possible surgical intervention are of great importance in the detection and treatment of bilateral tubal pregnancy.

## ACKNOWLEDGMENT

We duly sought for and obtained permission from the patient to publish this report with pictures anonymously. Ethical approval was also granted by the ethics committee of our hospital to report case.

**Conflict of Interest: Nil**

## REFERENCES

1. Andrews J, Farrell S. Spontaneous bilateral tubal pregnancies: a case report. *J Obstet Gynecol*

- Can 2008; 30:51-54.
2. Martinez J, Cabistany AC, Gonzalez M, Gil O, Farrer M, Romero JA. Bilateral simultaneous ectopic pregnancy. *South Med J* 2009; 102:1055-1057.
  3. Rizk B, Morcos S, Avery S, Elder K, Brinsden P, Mason B, et al. Rare ectopic pregnancies after in vitro fertilization: one unilateral and four bilateral tubal pregnancies. *Hum Reprod* 1990; 5:1025-1028.
  4. Adair CD, Benrubi GI, Sanchez-Ramos L, Rhatigan R. Bilateral tubal ectopic pregnancies after bilateral partial salpingectomy: a case report. *J Reprod Med* 1994; 39:131-133.
  5. Al-Quraan GA, Al-Taani MI, Nusair BM, El-Masri A, Arafat MR, Khateeb MM. Spontaneous ruptured and intact bilateral tubal ectopic pregnancy. a case report. *East Mediterr Health J* 2007; 13:972-974.
  6. Kansaria J, Chauhan A, Mayadeo N. An unusual case of bilateral tubal ectopic pregnancy [Internet]. *Bombay Hosp J* 2002; 44. Available from:[http://www.bhj.org/journal/2002\\_4401\\_jan/case](http://www.bhj.org/journal/2002_4401_jan/case)
  7. Jignesh Kansaria, Anahita C, Niranjana M. An unusual case of Bilateral tubal ectopic Pregnancy. *J Reprod Med* 2005; 50(3): 222-224.
  8. Norris S; Bilateral simultaneous tubal pregnancy. *CAN Med Assoc J* 1953;68:379-381
  9. Fox ET, Mevs FF. Simultaneous bilateral tubal pregnancies, report of 2 cases. *Obstet Gynecol* 1963; 21:499-501.
  10. Sebastiano C, Vincenzo C, Pietro G. Bilateral tubal pregnancy following in vitro fertilization and embryo transfer. *Eur J Obstet Gynecol Rep Bio* 2003; 110(2): 237-239.
  11. Marpeau O, Barranger F, Cortez A, Uzan S. Bilateral tubal pregnancy after natural conception: a case report. *J Reprod Med* 2005; 50:222-224.
  12. Shetty JP, Shetty B, Rao C, Makannavar JH, A rare case of bilateral tubal pregnancy *J Indian Med Assoc.* 2011; 109(7):506-7.
  13. Fishback HR. Bilateral simultaneous ectopic pregnancy. *Am J Obstet Gynecol* 1939; 37:1035.
  14. Edelstein MC, Morgan MA. Bilateral simultaneous tubal pregnancy: case report and review of literature *Obstet Gynecol Surv* 1989; 44: 250-252
  15. Ryan MT, Saldana B. Bilateral ectopic pregnancy: a tale of caution. *Acad Emerg Med* 2000; 7:1160-1163.
  16. De Graaf FL, Demetroulis C. Bilateral tubal ectopic pregnancy: diagnostic pitfalls *BrJ Clin Pract* 1997; 51: 56-58
  17. Hugues J, Olszewska B, Dauvergne P, Bulwa S, Cedrin-Durnerin I. Two-step diagnosis of bilateral ectopic pregnancy after in vitro fertilization. *J Assist Reprod Genet* 1995; 12: 460-462
  18. Jurkovic D. Ectopic pregnancy. In: Edmonds DK, editor. *Dewhurst's Textbook of Obstetrics and Gynaecology*. 7th ed. Massachusetts: Blackwell Publishing; 2007. p.106-16.
  19. Onuigbo IB, Eze JN, Okafor II. Twin proneness associated with two extraordinary cases of coexistence of bilateral tubal pregnancies. *J Coll Med* 2007;12:5-7
  20. Azubike JC. Multiple births in Igbo women. *Br J Obstet Gynaecol* 1982; 89:77-9.
  21. Egwuatu VE, Ozumba BC. Unexpectedly low ratio and falling incidence of ectopic pregnancy in Enugu, Nigeria. 1978-1981. *Int.J.Fertil* 1987; 32:113-21
  22. Eze JN. Successful intrauterine pregnancy following salpingostomy: Case report *Niger J Med* 2008; 17: 360-362.
  23. Schenker JG, Evron S. New concepts in the surgical management of tubal pregnancy and the consequent postoperative results. *Fertil Steril* 1983; 40:709-723
  24. Eze JN, Obuna JA, Ejikeme BN, Bilateral tubal pregnancies; A report of two cases, in Enugu, Nigeria: *Ann of African medicine* 2012; 11:112-115.
  25. Kelly AJ, Sowter NC, Trinder J. The management of tubal pregnancy London: RCOG Press; 2004.
  26. Sommer EM, Reisenberg K, Bogner G, Nagele F. Laparoscopic management of an unrecognized spontaneous bilateral tubal pregnancy. *Acta Obstet Gynecol Scand* 2002; 81(4): 366-68.
  27. Takeuchi K, Kitagaki S, Koketsu I. Bilateral tubal pregnancy treated with laparoscopy. *Int J Gynecol Obstet* 1995; 51:259-60.