



The Effect of Glycine Treatment on Histomorphometric Changes in the Diabetic Rat Retina

Soghra Gholami^{1*} and Mohammad Reza Rostamzad¹

¹Department of Basic sciences, School of Veterinary Medicine, Shiraz University, Shiraz, Iran
Corresponding Email: gholami@shirazu.ac.ir

ABSTRACT

Diabetic retinopathy is a major cause of blindness and one of its possible mechanisms is impairment in proteins and amino acids synthesis due to impairment in glucose synthesis. So far, different amino acids have been used to improve diabetic retinopathy. However, no research has been done till now about the effect of glycine on histological changes of diabetic rats retina. So, this is the main goal of the current study. 40 adult male Wistar rats weighing approximately 200- 250 g were prepared and divided into 4 groups of 10 each, which include: the first group (the rats were kept without receiving any material), the second group (healthy, the rats were received glycine at concentration of 130 mM, 1 %w/v), the third group (diabetic, the rats were kept without receiving any material), the fourth group (diabetic, the rats were received glycine at concentration of 130 mM, 1 %w/v). All rats were anesthetized after 16 weeks The separated retina was immersed in glutaraldehyde 4% for 3-4 h. Retina tissue was rinsed with buffer, post fixed in osmium tetroxide 1% and dehydrated through a graded ethanol series. The tissue was then placed in a mixture of propylene oxide and TAAB resin and transferred in pure resin. Semithin sections was prepared and viewed under light microscope (LM). Ultrathin sections were prepared, stained, and Viewed under TEM. Studies and evaluation of the thickness of IPL, INL, OPL, ONL, PSL and GCL. After preparing slides from the samples and staining with toluidine blue stain, they were examined and compared with light microscopy. The results showed that a significant decrease in the thickness of PSL and ONL and a significant increase in the thickness of IPL were observed in the group received glycine compared to the normal group ($P \leq 0.05$). There was a decrease in the thickness of all layers except PSL and IPL in the diabetic group compared to the normal group. These changes were not statistically significant. The thickness of whole retina and its layers were increased significantly in diabetic group received glycine compared to other groups ($P \leq 0.05$). Glycine increases the thickness of retinal layers in the retinopathic group through its anti-diabetic properties as well as its influence on improvement of protein synthesis in retina; so, treatment with glycine is recommended to improve different layers of retina in diabetic patients with retinopathy.

Keywords: Glycine, Histomorphomeric, Retina, Diabetes

INTRODUCTION

Diabetes is dramatically increasing in all around the world and in Iran and every year a large number of patients with the disease are faced with serious troubles or lose their lives. One of the most common and the major disorders caused by diabetes is diabetic retinopathy [1, 2]. A large number of patients with retinopathy may experience blindness. Provided statistics from the prevalence of blindness induced by diabetic retinopathy is relatively high with regard to the prevalence of diabetes in various countries and more than ten thousand patients with retinopathy will have vision loss every year [3, 4]. Approximately 10 to 18% of patients with simple retinopathy are progressed toward proliferative form and approximately half of the patients are faced with blindness within 5 years [5]. Pain and complications of these patients will reduce by early diagnosis of retinopathy. In fact, the progression of the disease to severe stages and its exorbitant cost will be prevented by control of it [5]. One of the possible mechanisms of retinal damage is a disorder in amino acids metabolism.

The anti-diabetic activity of free amino acids has been of great interest. Inhibition of proteins glycation may be useful in delaying incidence of complications in patients who suffer from diabetes mellitus [6]. Some amino acids including lysine, arginine, aspartic acid and glutamic acid have different degrees of anti-glycation effects [24]. Glycine in another study has effects in reducing hyperglycemia, hypercholesterolemia and glycated hemoglobin levels in rats with diabetes [9]. It has also observed that glycine improves sensitivity and response to insulin in type 2 diabetes animal models and improves related symptoms to it [10]. Given to the importance of evaluation of retinopathy in order to prevent blindness phenomena which is an irreversible mental disorder and given to the improving effects of glycine in improvement of diabetes; and by taking into account the fact that no study has been conducted till now on the effects of glycine on changes in retinal tissue in diabetic groups; this study is aimed to evaluate the effect of glycine on histomorphometric changes of diabetic rat retina.

MATERIAL AND METHODS

This study was conducted completely random and under in vitro conditions. All ethics of working with laboratory animals were respected in the research based on the guidelines of Laboratory Animals Protection and Welfare Committee of Shiraz University. A total number of 40 adult male Wistar rats of 100-120 days old and weighing 200-250 g were prepared from Razi Vaccine and Serum Research Center of Shiraz. The rats were kept in Laboratory Animal House related to Shiraz University of Veterinary Medicine for 2 weeks and under laboratory conditions including 21 ± 2 °C temperature and a cycle of 12 hours of light and 12 hours of darkness. The animals were housed in metallic cages with latticed doors. They were also fed from standard food. Water was provided for them in especial glass bottles. Their cages were disinfected with alcohol 70% three times a week. The rats were then divided into 4 groups of 10 each:

The first group: included, 10 healthy rats that freely consumed water and food.

The second group: included, 10 healthy rats that freely received glycine in drinking water at concentration of 130 Mm and 1% w/v.

The third group: included, 10 diabetic rats that freely consumed water and food.

The fourth group: included, 10 diabetic rats that freely received glycine in drinking water at concentration of 130 Mm and 1% w/v.

20 rats placed in diabetic groups (the third and the fourth groups) were selected for induction of diabetes. This process was performed by intraperitoneal injection of streptozotocin (STZ) at a dose of 65 mg/kgbw. The measurement of fasting plasma glucose was done before injection and 24 hours after injection of STZ to confirm diabetes. The measuring process repeated again a week after injection to assure from maintenance and stabilization of the disease. The cases with blood sugar higher than 240 mg/dl were considered as diabetic cases and were used for the experiment [11-13].

After an approximate period of 16 weeks, the rats were anesthetized by intraperitoneal injection of higher doses of ketamine and xylazine.

Preparation of tissue for microscopy

The separated retina was immersed in glutaraldehyde 4% for 3-4 h. Retina tissue was raised with buffer, post fixed in osmium tetroxide 1% and dehydrated through a graded ethanol series. The tissue was then placed in a mixture of propylene oxide and TAAB resin and transferred in pure resin. Semithin sections was prepared (Microtome: c. reichert, Austriaomu3) and viewed under light microscope (LM). Ultrathin sections were prepared, stained, and Viewed under TEM.

Studies and evaluation of the thickness of IPL, INL, OPL, ONL, PSL and GCL. After preparing slides from the samples and staining with toluidine blue stain, they were examined and compared with light microscopy. The obtained information was then examined using one way analysis of variance (one-way ANOVA) test and Duncan test (at significance level of $P \leq 0.05$).

RESULTS

According to the results, a significant decrease in the thickness of PSL and ONL and a significant increase in the thickness of IPL were observed in the group received glycine compared to the normal group ($P \leq 0.05$). There was a decrease in the thickness of all layers except PSL and IPL in the diabetic group compared to the normal group.

These changes were not statistically significant. The thickness of whole retina and its layers were increased significantly in diabetic group received glycine compared to other groups ($P \leq 0.05$).

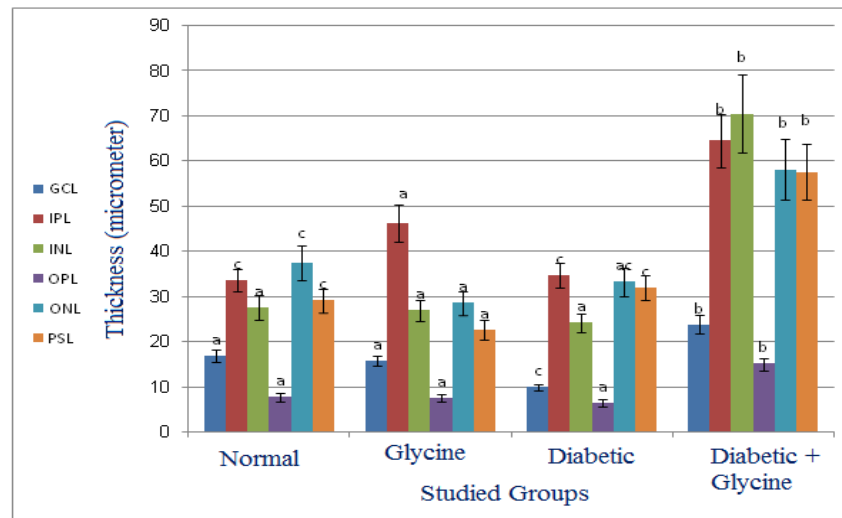


Figure 1. The comparison of the thickness of different layers in the studied groups (mean \pm standard deviation (SD))
*Dissimilar letters indicate significant difference ($P \leq 0.05$).

DISCUSSION

The results of this study showed that there was a reduction in the different layers of the retina except in IPL and PSL in the diabetic group; although the changes were not statistically significant compared to the normal group, but they reflected the negative impact of diabetes on the various layers of the retina. Investigations have revealed that retinopathy and retinal damage are both the signs of diabetes [8, 14, 15]. In addition, impairment in vision and blindness is observed due to retinopathy [16]. Investigations found that retina launches the visual activity and image capturing due to the use of glucose as an energy source [17]. Thus, impaired glucose metabolism causes disorder in retinal nervous system [18] that associates with inflammation and gradual reduction of the thickness of the retinal different layers. This occurs probably due to collapse of nervous section, change in physiology of the retina and impairment in glucose transportation of retinal layers [19]. Studies have indicated that reduction in various layers of the retina is observed in a time dependent manner in streptozotocin-induced diabetic mice, so that destruction of retinal tissue is also increased by progress of diabetes [14]. Studies have also expressed that after 10 to 12 weeks of diabetes, the thickness of the retina in mice was significantly lower than the control group, which reflected the negative impact of diabetes on retinal changes [20]. This agrees with the results of the current study.

Previous studies have suggested that diabetes increases apoptosis in the inner retina, where the retinal ganglion cells live [21, 22]. Findings have suggested that neuronal apoptosis is significantly occurred faster than vascular apoptosis and data have indicated that apoptosis is in primary neural network of the retina, and even remains stable in diabetic patients. Since neurons do not have the ability of reproduction, so apoptosis of these cells leads to their aggregate analysis due to chronic neurodegeneration. This event is due to lack of glucose and its effects on glucose metabolism [14]. It has found in studies conducted in rats with diabetes that the total number of cell bodies in ganglion cell layers of the retina reduces up to 10% followed by 7.5 month from progress of diabetes. It has associated with reduction (up to 22%) in the thickness of inner plexiform layer and reduction (14%) in the thickness of inner nuclear layer. The impairment in glucose as a substrate in the activities of the retina is considered as a reason for all of the above reductions. It is also possible that in this study impairment in physiology of the retina and eventually death of nerve cells have occurred due to the impairment in glucose metabolism; and reduction of the thickness of retinal layers, which observed in this study, is a proof of this issue. This agrees with the results of previous researches.

Studies have suggested that there are several assumptions relating to glucose in incidence of diabetic complications that include: increase in aldose reductase pathway, formation of advanced glycation end products (AGEs), oxidative stress, carbonyl stress and increase of protein kinase C (PKC) pathway [23]. It is likely that the reduction of some layers of the retina occurred in this study to be due to one of the above mentioned mechanisms. It has also expressed that non-enzymatic reaction of glucose with free amino groups of some of proteins with long half-life leads to accumulation of AGEs. It is considered as an important mechanism in pathogenesis of diabetes mellitus complications that eventually these products, in turn, have the ability to form intermediate covalent bond with some proteins (e.g. collagen and laminin), thus leading to stiffness of extracellular matrix and progression of retinopathy

[23]. Actin, which is considered as a cytoskeleton protein, is prone to glycation. Glycation of available actin in cytoskeleton of axon may interfere with coordination of cytoskeleton activities in terms of functional and structural, which have attributed to pathogenesis of diabetic neuropathy. Non-enzymatic glycation of actin may be at least responsible for reduction of deformability of leukocytes that leads to blockage of the capillaries in the retina and eventually causes completion of retinopathy [24]. It is likely in the current study that the non-enzymatic reaction of glucose with some proteins, such as actin, causes disturbance in the layers of the retina and retinopathy, which is consistent with the results of previous researches.

Other studies have expressed that since insulin has impact on proteins and amino acids, convenient and adequate access to amino acids is of particular importance to prevent adverse effects of diabetes mellitus, since reduction of amino acids can be counted as an important factor in etiology of diabetes complications [25, 26]. The probability also exist in this study that glucose may be the reason of impairment in metabolism of proteins and amino acids.

On the other hand the results of this study showed that the thickness of the layers of the retina in the diabetic groups treated with glycine had an increase compared to the diabetic and normal groups. This reflects the positive effects of glycine on changes in the retina in diabetic rats. Studies have suggested that free amino acids alleviate glycosylation of eye's lens proteins, resulting in delay of cataract incidence and have blood glucose-lowering effects in rats with diabetes [27, 28]. In addition, free amino acids in vitro conditions reduce glycation of actin cytoskeleton [24]. It has clarified that amino acids competitively inhibit binding of glucose to proteins through different mechanisms of quality of amino acids effect in modulating diabetes and in this way cause protection. This process is considered as the first cascade pathway of glycation, [29]. Some other amino acids can relieve pathological pathways such as oxidative stress and as a result stimulate sensitivity of tissue to insulin. Studies have indicated that prescription of glycine reduces the complications of diabetes in STZ-induced diabetic rat models that is probably caused by inhibition of non-enzymatic glycation process. These rats have revealed a significant reduction in clouding of the eye's lens and microaneurysms [30]. It has also stated that orally administration of glycine in diabetic rats inhibits from progression of cataracts. This effect is probably due to its anti-glycation properties [31]. The possibility also exists in this study that the increase in the thickness of the different layers of the retina compared to the diabetic group is due to anti-diabetic properties of glycine and development of the mentioned mechanism. It is likely that in the healthy groups that there is no impairment in the mechanisms of glucose and other retinal proteins; so, administration of glycine to rats is considered as a harmful factor, so that in the current study the reduction of the thickness of retinal layers was observed.

CONCLUSION

Based on the results and mentioned issues, it was found that diabetes makes damage to different layers of the retina due to the impairment in the metabolism of glucose and effective proteins in the thickness of the retina. Glycine by its anti-diabetic properties as well as improvement in protein synthesis in the retina leads to increase in the thickness of the layers of the retina in the retinopathy group. Therefore, treatment with glycine is recommended to improve different layers of the retina in diabetic patients with retinopathy.

Acknowledgement

We thank the University of Shiraz for financial support in this research.

REFERENCES

- [1] Hutchinson A, McIntosh A, O' Keeffe, Khunti K, Baker R, Booth A. Effectiveness of screening and monitoring tests for diabetic retinopathy: a systematic review. *Diabet Med* 2000; 17: 490-506
- [2] Klein R, Klein BE, Moss SE, Cuickshanks KJ. The Wisconsin epidemiological study of diabetic retinopathy. XV. The long term incidence and macular edema. *Ophthalmology* 1995; 102:7-10
- [3] Harris MI Undiagnosed NIDDM: clinical and public health issues. *Diabetes Care* 1993; 16: 642-52
- [4] Boehm IH, Sosna T, Andersen HL, Porta M. The eyes in diabetes and diabetes through the eyes. *Diabetes Research* 2007; 78: 1-21.
- [5] Akbar Zadeh, S., Mani KashaniKh. The prevalence of diabetic retinopathy and its related factors in diabetic patients. *Medical Journal of Tabriz University of Medical Sciences*. 2006; 28(2): 15-18.
- [6] Vlassara, H., Brownlee, M., Manogue, K.R., Dinarello, C.A., Pasagian, A. (1988) *Science*, 240, 1546.
- [7] Sulochana, K.N., Ramakrishnan, S., Rajesh, M., Coral, K. and Badrinath, S.S. (2001) *Curr. Sci.*, 80, 133.
- [8] Gholami S, Saberi M. 2015. Histomorphometric alterations in Aleovera gel extract treatment in the diabetic rats retina. *Comparative clinical pathology*, 24: 1021- 1029.
- [9] Alvarado-Vásquez, N., Zamudio, P., Cerón, E., Vanda, B., Zente no, E. and Carvajal-Sandoval, G. (2003) *Comp. Biochem. Physiol. C. Toxicol. Pharmacol.*, 134, 521.

- [10] González-Ortiz, M., Medina-Santillán, R., Martínez-Abundis, E. and von Drateln, C.R. (2001). Effect of glycine on insulin secretion and action in healthy first-degree relatives of type 2 diabetes mellitus patients. *Horm. Metab. Res.*, 33, 358.
- [11] Asadi, F and colleagues. The therapeutic effects of *Cuminum odoratum* on experimental diabetes in male rats. *Proceedings of Iran's Fourteen Congress of Physiology and Pharmacology*. 1999. Pp: 347.
- [12] Roghani, M and colleagues. The analgesic effect of aqueous extract of fenugreek in male rats with STZ-induced diabetes mellitus using Farmalyn test during both acute and chronic phases. *Proceedings of Iran's Fourteen Congress of Physiology and Pharmacology*. 1999. Pp: 342.
- [13] Nikbakht, M., Ghayasi, IzadPanah. The hypoglycemic effect of aqueous-alcoholic extract of gall in STZ-induced diabetic and normoglycemic male rats. *Armaghan Danesh Scientific Journal*. 2006, 63-71: 42.
- [14] Saberi M, Gholami S. 2012. An investigation on the effects of the Aloe Vera extract on the thickness of the retina in male diabetic rats. *Iranian Journal of Veterinary Research, Shiraz University*; 13 (4): 296- 302.
- [15] John, EH (2011). *Diabetes mellitus guyton and hall textbook of medical physiology*. 12th Edn., Philadelphia, W. B. Saunders Co. Elsevier. PP: 944-953.
- [16] Mensah, E and Kohner, E (2002). Diagnosis and management of diabetic retinopathy. *Top. Endocrin.*, 19: 14-18.
- [17] Park, SH; Park, JW and Park, SJ (2003). Apoptotic death of photoreceptors in the streptozotocin-induced diabetic rat retina. *Diabetologia*. 46: 1260-1268.
- [18] Daley, M; Watzke, R and Riddle, M (1987). Early loss of blue-sensitive color vision in patients with type I diabetes. *Diabetes Care*. 10: 777-781.
- [19] Kumagai, AK; Glasgow, BJ and Pardridge, WM (1994). GLUT1 glucose transporter expression in the diabetic and nondiabetic human eye. *Invest. Ophthalmol. Vis. Sci.*, 35: 2887-2894.
- [20] Martin, PM; Roon, P; Van Ells, TK; Ganapathy, V and Smith, SB (2004). Death of retinal neurons in streptozotocin-induced diabetic mice. *Invest. Ophthalmol. Vis. Sci.*, 45: 3330-3336.
- [21] Hammes HP, Federoff HJ, Brownlee M. Nerve growth factor prevents both neuroretinal programmed cell death and capillary pathology in experimental diabetes. *Mol Med*. 1995;1:527-534.
- [22] Kerrigan LA, Zack DJ, Quigley HA, Smith SD, Pease ME. TUNEL- positive ganglion cells in human primary open-angle glaucoma. *Arch Ophthalmol*. 1997;115:1031-1035.
- [23] Tsilibary, E.C., Koliakos, G.G., Charonis, A.S., Vogel, A.M., Re ger, L.A. and Furcht, L.T. (1988). The effect of non-enzymatic glycosylation on the binding of the main noncollagenous NC 1 domain to type IV collagen. *J. Biol. Chem.*, 263, 19112.
- [24] Sulochana, K.N., Indra, C., Rajesh, M., Srinivasan, V. and Ramakrishnan, S. (2001) *Glycoconj. J.*, 18, 277.
- [25] Kalpana MB, Sriram GP, Subramanian S. (2014). Studies on the antidiabetic activity of *Ananas comosus* leaves in STZ induced diabetic rats. *Der Pharmacia Lettre*, 6 (2): 22- 30.
- [26] Franke, S., Stein, F., Dawczynski, J., Blum, M., Kubetschka, U., Stein, G. and Strobel, J.J. (2003). Advanced glycation end-products in anterior chamber aqueous of cataractous patients. *Cataract Refract. Surg.*, 29, 329.
- [27] Sulochana, K.N., Punitham, R. and Ramakrishnan, S. (1998). Beneficial effect of lysine and amino acids on cataractogenesis in experimental diabetes through possible antiglycation of lens proteins. *Exp. Eye Res.*, 67, 597.
- [28] Ramakrishnan, S. and Sulochana, K.N. (1993). Decrease in glycation of lens proteins by lysine and glycine by scavenging of glucose and possible mitigation of cataractogenesis. *Exp. Eye Res.*, 57, 623.
- [29] Manduteanu, I., Calb, M., Lupu, C., Simionescu, N. and Simionescu, M. (1992). Increased adhesion of human diabetic platelets to cultured valvular endothelial cells. *J. Submicrosc. Cytol. Pathol.*, 24, 539.
- [30] Alvarado-Vásquez, N., Lascrain, R., Cerón, E., Vanda, B., Carvajal-Sandoval, G., Tapia, A., Guevara, J., Montañó, L.F. and Zente no, E. (2006). Oral glycine administration attenuates diabetic complications in streptozotocin-induced diabetic rats. *Life Sci.*, 79, 225.
- [31] Bahmani F., Bathaie S. Z., Aledavood S. J., Ghahghaei A. 2012. Glycine therapy inhibits the progression of cataract in streptozotocin-induced diabetic rats. *Mol. Vis.* 18: 439-448.